

## Patient with Hypertrophic Cardiomyopathy Combined and Atrioventricular Conduction Disturbance

Andres M<sup>1\*</sup>, Rajs T<sup>1</sup>, Żmudka K<sup>1</sup>, Legutko J<sup>1</sup>

<sup>1</sup>Department of Interventional Cardiology, John Paul II Hospital, Krakow, Poland

Volume 3 Issue 1- 2020

Received Date: 22 Feb 2020

Accepted Date: 14 Mar 2020

Published Date: 19 Mar 2020

### 2. Key words

Transthoracic; Myopathy; Intra-ventricular; Bradycardia

### 1. Abstract

53 years old Caucasian male patient with suspected aortic valve stenosis and coexisting left ventricle wall hypertrophy was referred to clinical department of interventional cardiology aiming cardiologic diagnostics and determine further treatment. Transthoracic echocardiography revealed preserved global and regional ejection fraction, concentric hypertrophy of left ventricle, increased gradient through left ventricle outflow tract pressure measured as 84.9/40.8 mmHg without any relevant changes of heart valves. Angiography did not reveal any hemodynamically significant atherosclerotic plaques in coronary arteries. Patient was disqualified from surgical treatment and qualified to implantation of dual chamber pacemaker with permanent, sequential atrioventricular pacing with short programmed atrioventricular interval (due to episodes of bradycardia and pauses longer than 4 seconds). At follow up visit in outpatient clinic 4 weeks after the procedure patient reported considerable improvement of physical activity, denied dyspnoea and other exertional complaints. Control transthoracic echocardiography revealed significant reduction of gradient measured in left ventricle outflow tract.

### 3. Introduction

Hypertrophic Cardio Myopathy (HCM) is a form of the primary Cardio Myopathy and is defined by thickened myocardium to equal or more than 15 mm in diastole regarding at least one segment of left ventricle wall. Moreover, mentioned thickening cannot be explained by other cause such as uncontrolled hypertension, significant valve disease or practicing professional sport [1, 2]. Incidence of HCM ranges from 0,02% to 0,023% with slightly more men [3-5]. Among more than 60% of patients, HCM is characterized by autosomal dominant inheritance pattern and the most often cause is mutation of genes encoding myocardial sarcomer proteins. Other defects may affect genes encoding  $\beta$ -myosin heavy chain, myosin binding protein-C or cardiac troponin I and T [6-8]. Other cases of HCM may result from inherited metabolic or musculoskeletal diseases, but can also occur in non-genetic diseases such as amyloidosis [9, 10]. In the rest 30% of cases the underlying cause cannot be found.

Due to diverse aetiology of the disease, every significant thickening of left ventricle wall should lead to deep differential diagnosis aiming explanation of the cause.

### 4. Case Report

53 years old male with concomitant atherosclerosis risk factors, suspicion of symptomatic aortic valve stenosis and coexisting left ventricle wall hypertrophy was admitted to Interventional Cardiology Department in order to conduct a differential diagnosis and determine further treatment.

In the past medical history patient reported dyspnoea in II/III NYHA functional class, intermittent non typical chest discomfort, palpitation and two faint episodes. Amongst co morbidities there should be mentioned hyperlipidemia (treated using atorvastatin 20 mg), chronic kidney disease and third degree obesity (body weight 142 kg, height 180 cm, BMI 43,8 kg/m<sup>2</sup>, BSA 2,66 m<sup>2</sup> according to Mosteller formula). Family history regarding cardiac, metabolic, systemic diseases or cases of sudden cardiac death was negative. In physical examination heart rate was 60 per minute, there were distinct heart beats with concomitant systolic murmur reaching 5/6 points according to the Levine scale over apex without pulmonary congestion and with little oedema around ankles. In the laboratory tests slight impairment of renal function was found (creatinine level 166  $\mu$ mol/L [normal 62-106], eGFR 40 ml/min/1,73 m<sup>3</sup> [60

\*Corresponding Author (s): Marek Andres, Department of Interventional Cardiology, John Paul II Hospital, Krakow, Poland, Tel: (0048)500206464, Fax: (0048) 12 614 30 47, E-mail: marekan-

Citation: Andres M, Patient with Hypertrophic Cardiomyopathy Combined and Atrioventricular Conduction Disturbance. Annals of Clinical and Medical Case Reports. 2020;3(1):1-4.

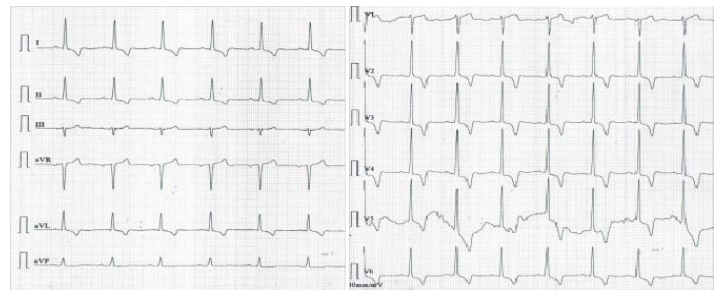


ml/min/1,73 m<sup>3</sup> lower limit of normal], urea 11,7 mmol/L [8,3 mmol/L upper limit of normal]. Standard electrocardiogram revealed sinus rhythm 65/min, normal axis, PQ 200 ms, QRS 80 ms, QTc 437 ms, left ventricle hypertrophy (Sokolow index 3,8 mV, R in aVL 1,2 mV), secondary changes of ST – T due to left ventricle hypertrophy and deep negative T waves (up to 9 mm) in I, II, aVL, V2-V6 leads (Figure 1). Trans thoracic echocardiography performed with Philips CX 50 revealed preserved global and regional ejection fraction, enlargement of right (area 24 cm<sup>2</sup>) and left (area 23 cm<sup>2</sup>) atrium, concentric hypertrophy of left ventricle (intraventricular septum 25 mm, left ventricle posterior wall 16-18 mm), increased gradient through left ventricle outflow tract measured as 84.9/40.8 mmHg (velocity time interval) without any relevant changes of heart valves, including absence of aortic valve stenosis (Figure 2). Ultrasound examination of abdomen disclosed slight liver enlargement, but laboratory tests revealed correct level of aspartate and alanine aminotransferase and absence of light chains of immunoglobulin in plasma. Moreover there was none deviation in urine examination. In further diagnostic, magnetic resonance of heart with gadolinium late enhancement was performed and confirmed concentric hypertrophy of left ventricle marked specially in basal and medial segment of intraventricular septum (23 mm maximum) with focal points of fibrosis. Examination additionally revealed systolic narrowing of left ventricle outflow tract with specific for SAM movement of anterior leaflet of mitral valve towards intraventricular septum (Figure 3). Due to episodes of bradycardia observed during hospitalisation beta-blocker drug was (bisoprolol 5 mg) withdrawn and 48 hours ECG Holter monitoring revealed episodes of bradycardia (20 bpm) and numerous pauses longer than 4 seconds. Coronary angiography performed via right radial artery did not reveal any hemodynamically significant atherosclerotic plaques in coronary arteries. Additionally course of coronary arteries was sinuous and myocardial bridge over middle segment of left anterior descending artery narrowing its lumen around 30% was found (Figure 4). Despite withdrawal of nephrotoxic drugs (spironolactone 50 mg) and proper hydration, after the procedure (80 ml of omnipaque 350) occurred deterioration of renal function, which fulfilled the criteria of contrast induced nephropathy. Mentioned deterioration was dissolved via intensive intravenous fluid intake with further full recovery.

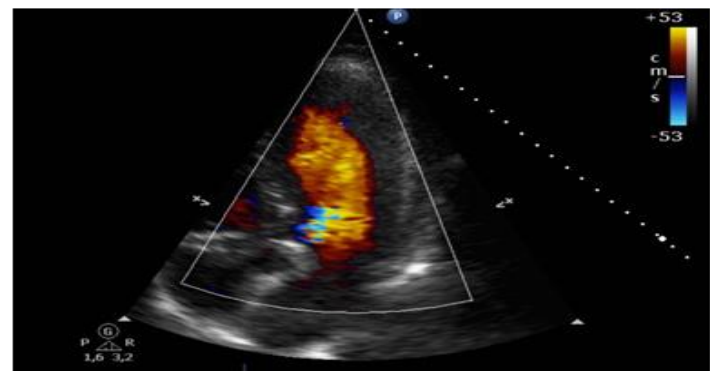
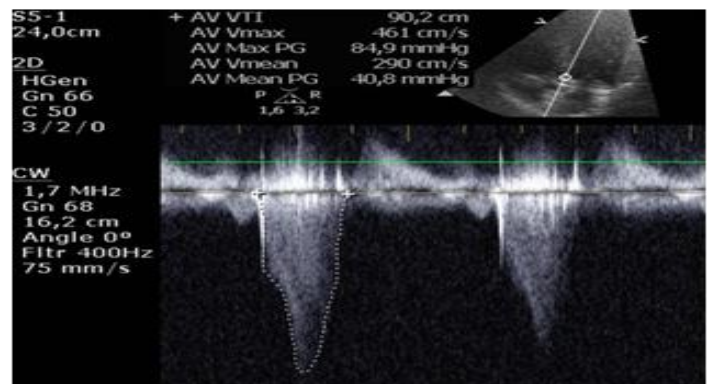
Patient was consulted by local Heart Team and was finally disqualified from surgical treatment (intraventricular septum myectomy modo Morrow), because of unacceptably high risk of surgery and also from septal alcohol ablation due to unfavorable anatomical characteristics. Patient was however qualified to implantation

of dual chamber pacemaker with permanent, sequential atrioventricular pacing with short programmed atrioventricular interval. At the same time patient did not fulfil criteria for implantable cardioverter defibrillator due to low (3,46%) 5-year risk of sudden cardiac death estimated by HCM Risk Score calculator.

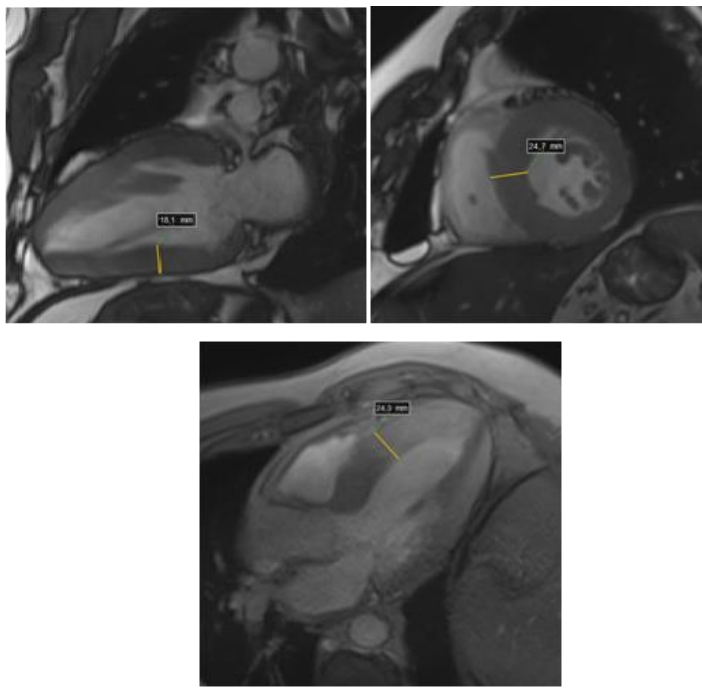
At follow up visit in outpatient clinic 4 weeks after the procedure patient reported considerable improvement of physical activity, denied dyspnoea and other exertional complaints. Control transthoracic echocardiography revealed significant reduction of gradient measured in left ventricle outflow tract at the level of 26,9/16,0 mmHg (Figure 5).



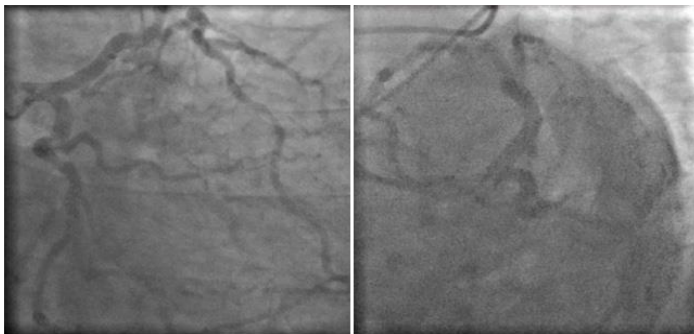
**Fig. 1.** Electrocardiogram. Sinus rhythm 65/min, normal axis, PQ 200 ms, QRS 80 ms, QTc 437 ms, left ventricle hypertrophy (Sokolow index 3,8 mV, R in aVL 1,2 mV), secondary changes of ST – T due to left ventricle hypertrophy and deep negative T waves (up to 9 mm) in I, II, aVL, V2-V6 leads.



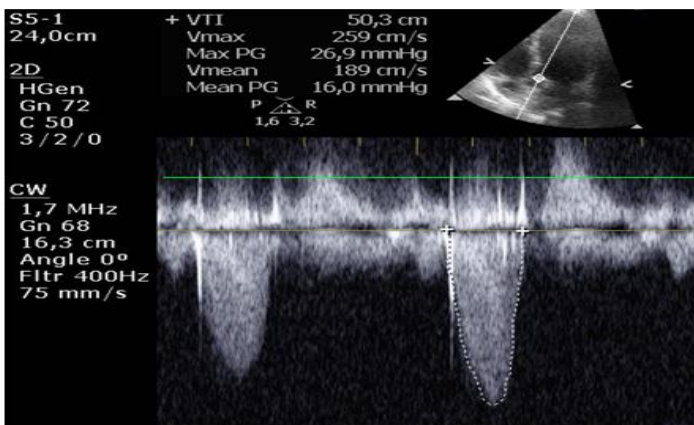
**Figure 2:** Transthoracic echocardiography. The apical five-chamber view. Typical HCM flow spectrum in LVOT obtained with continuous-wave doppler. Maximum gradient in LVOT 84.9 mmHg, medium gradient 40.8 mmHg (A). Laminar blood flow in the left ventricle with turbulence in the LVOT (B).



**Fig. 3.** Magnetic resonance imaging of the heart. Examination in the cineMR sequence. A - double chamber projection in diastole, the thickness of the bottom wall segment is 18.1 mm; B - projection on the short axis in diastole; C - projection on the outflow tract of the left ventricle in diastole. The thickness of the medial segment of the inferior septum measured in the short projection and the projection directed to the left ventricular outflow path (B, C) is about 24.5 mm.



**Figure 4:** Coronary angiography of the left coronary artery. A - Projection RAO 30° + CAU 30°  
B - Projection LAO 45° + CAU 45°. Coronary vessels without significant stenoses.



**Figure 5:** Follow up. Transthoracic echocardiography. The apical five-chamber view. Continuous-wave doppler directed to the LVOT; gradient 26.9/16.0 mmHg.

## 5. Discussion

Taking into account a very diverse aetiology of HCM, every detection of thickened myocardium of left ventricle wall should lead to deep differential diagnosis. Diagnostic path should include specialistic laboratory tests and in some cases genetic and family tree analysis to discover onset of the disease and identify members of the family with genomic burden. Course of the disease and its clinical picture may be varied. Many patients are asymptomatic and diagnosis may be accidental or made as a result of screening tests. Some patients suffers from anginal pain, dyspnoea, palpitation, signs of heart failure or syncope. Angina may occur as result of atherosclerosis or microcirculation disturbances, significant narrowing of left ventricle outflow tract, increased left ventricle wall load or anomalies of coronary arteries such as myocardial bridge, which are reported more frequent in these group of patients [11]. Syncope may result from abnormal valvular reflexes, hypovolemia and wide variety of cardiac arrhythmias [12,13]. Unexplained syncope other than reflexive constitutes a serious risk factor for sudden cardiac death, especially among younger population [14]. Laboratory tests performed in patients with HCM should include renal, thyroid and liver function. Additionally lactate level (increased in some mitochondrial diseases), afa-galactosidase in plasma (low level in Anderson-Fabry disease), free immunoglobulin light chains in plasma (detected in 90% of cases of AL amyloidosis), but also morphology, fasting glucose, cardiac markers (troponin I and T) and natriuretic peptide B should be assessed. Echocardiographic examination constitutes basis of diagnosis and monitoring course of HCM. Thickening of myocardium affects mostly basal segments of intraventricular septum, but also lateral and posterior segment of intraventricular septum and the apex of left ventricle [15]. Particular attention should be paid to the presence of gradient in left ventricle, which could be caused by aortic stenosis, subaortal membrane, abnormalities of mitral valve leaflets and intraventricular narrowing. Additionally, a detailed diastolic function should be assessed, taking also into account tissue doppler imaging, velocities measured in pulmonary veins, systolic pressure in pulmonary artery and area of left atrium [14, 16]. Patients with suboptimal visualisation of structures in echocardiography should undergo cardiac magnetic resonance imaging with late gadolinium enhancement or computed tomography. Invasive coronary angiography or computed coronary angiography should be considered before every planned procedure on intraventricular septum in patients after sudden cardiac arrest, with permanent ventricular arrhythmias and with suspicion of coronary artery disease (especially after 40 years old). Further treatment depends on presence of clinical



symptoms, left ventricle outflow tract narrowing, risk of sudden cardiac death and presence of life-threatening arrhythmias. In patients with rest or induced left ventricle outflow tract obstruction first line treatment constitutes beta-blocker, devoid of additional vasodilatory effect, at maximum daily doses. In case of ineffectiveness, intolerance or contraindications, second option constitute calcium channel blockers such as verapamil or diltiazem. Particular attention should be paid to avoid dehydration, excessive alcohol intake and overweight. Indications to surgical treatment (intraventricular septum myectomy, alcohol ablation, cardiac pacemaker or cardioverter defibrillator implantation) are severe symptoms in NYHA III/IV functional class despite optimal pharmacological treatment at maximum tolerable doses, recurrent exertional syncope and maximum gradient measured in LVOT equal to or greater than 50 mmHg. Choice between surgical treatment and alcohol ablation depends on meticulous analysis of intraventricular septum anatomy, its vasculature and also structure of mitral apparatus. Surgical myectomy is preferred in case of thickness of intraventricular septum more than 30 mm, extensive scarring concluded on the basis of cardiac magnetic resonance imaging with concomitant at least moderate mitral regurgitation. Before qualification to alcohol ablation procedure it is necessary to perform contrast-enhanced echocardiography with assessment of collection of contrast in intraventricular septum. It is not recommended to administer alcohol into numerous septal branches, because of high risk of complications and probability of arrhythmic incidences [18]. Also other methods of embolization of intraventricular septum are described, such as using coils [19], cyanoacrylate [20] or direct intracellular ablation via radiotherapy [21]. In this particular case due to symptomatic narrowing of left ventricle outflow track, absolute indications to cardiac pacing and disqualification from surgical treatment, implantation of dual chamber pacemaker was treatment of choice. Cases of effective reduction of gradient in left ventricle outflow track, symptoms and improvement of quality of life after applying permanent, sequential atrioventricular pacing with short atrioventricular interval are present in available literature [22]. It is essential to optimise parameters of stimulation to achieve maximal pre-excitation of apex, at the same time minimally affecting left ventricle filling (AV interval  $100 \pm 30$  ms at rest with adequate response during physical activity). On the other hand benefits of rate responsive stimulation regarding improvement of physical activity remain uncertain. It is not clear how consistent stimulation of right ventricle affects systolic function of left ventricle. All of these facts need to be taken into account, especially among patients without left ventricle outflow track obstruction. In patients with impaired

systolic function of left ventricle (EF <50%) implantation of cardiac resynchronization therapy device should be considered. In case of end stage heart failure or ventricular arrhythmias non-responding to pharmacological treatment heart transplant remains last option. Risk of sudden cardiac death assessed with HCM Risk-SCD calculator should be evaluated in every patient with hypertrophic cardiomyopathy [24]. Calculator assesses 5 year risk of sudden cardiac death on the basis of patients age, maximal diameter of left ventricle wall, diameter of left atrium, maximum gradient in LVOT, presence of non – sustained ventricular tachycardia in Holter ECG monitoring, unexplained syncope and previous cases of sudden cardiac death in patient`s family. Indications for implantation of cardioverter-defibrillator in primary prevention of sudden cardiac death are calculated risk equal or greater than 6% and concomitant life expectancy more than 1 year.

Patient with HCM require lifelong monitoring of changes in myocardium. In stable patients standard ECG examination, transthoracic echocardiography and 48 hours ECG Holter monitoring should be performed every 12-24 months. Patients with sinus rhythm and increased diameter of left atrium  $\geq 48$  mm ECG Holter monitoring lasting 48 hours should be performed every 6-12 months to estimate risk of sudden cardiac death and risk of stroke. In stable, asymptomatic patients exercise stress testing (optimally cardio-pulmonary stress testing) should be taken into consideration. Due to high probability of genetic component, genetic counselling for first degree relatives is strongly advisable.

## 6. Conclusion

Proceedings in patients with hypertrophic cardiomyopathy comprise differential diagnosis, seeking for secondary causes of thickening of left ventricle myocardium and also optimal pharmacological therapy aiming reduction of symptoms and slowing progression of the disease. Among patients non-responding for pharmacotherapy with symptoms resulting from significant LVOT obstruction procedural treatment should be considered. Risk of sudden cardiac death must be estimated in every patient and in presence of risk factors cardioverter defibrillator in primary prevention has to be implanted. All first degree relatives need genetic counselling.

## References

1. Elliott PM, Anastakis A, Borger MA, Borggrefe M, Cecchi F, Charon P et al. 2014 ESC Guidelines on diagnosis and management of hypertrophic cardiomyopathy: the Task Force for the Diagnosis and Management of Hypertrophic Cardiomyopathy of the European Society of Cardiology (ESC). *Eur Heart J*. 2014 Oct 14; 35(39): 2733-79.

2. O'Mahony C, Akhtar MM, Anastasiou Z, Guttman OP, Vriesendorp PA, Michels M et al. Effectiveness of the 2014 European Society of Cardiology guideline on sudden cardiac death in hypertrophic cardiomyopathy: a systematic review and meta-analysis. *Heart*. 2019 Apr; 105(8): 623-631.
3. Hada Y, Sakamoto T, Amano K et al. Prevalence of hypertrophic cardiomyopathy in a population of adult Japanese workers as detected by echocardiographic screening. *Am J Cardiol*. 1987; 59: 183-184.
4. Codd MB, Sugrue DD, Gersh BJ, Melton LJ III. Epidemiology of idiopathic dilated and hypertrophic cardiomyopathy. A population-based study in Olmsted County, Minnesota, 1975-1984. *Circulation*. 1989; 80: 564-572.
5. Maron BJ, Gardin JM, Flack, Gidding SS, Kurosaki TT, Bild DE. Prevalence of hypertrophic cardiomyopathy in a general population of young adults. Echocardiographic analysis of 4111 subjects in the CARDIA Study. Coronary Artery Risk Development in (Young) Adults. *Circulation*. 1995; 92: 785-789.
6. Van Driest SL, Ommen SR, Tajik AJ, Gersh BJ, Ackerman MJ. Yield of genetic testing in hypertrophic cardiomyopathy. *Mayo Clin Proc*. 2005; 80: 739-744.
7. Morita H, Rehm HL, Menesses A, McDonough B, Roberts AE, Kucherlapati R et al. Shared genetic causes of cardiac hypertrophy in children and adults. *N Engl J Med*. 2008; 358: 1899-1908.
8. Brito D, Miltenberger-Miltenyi G, Vale PS, Silva D, Diogo AN, Madeira H. Sarcomeric hypertrophic cardiomyopathy: genetic profile in a Portuguese population. *Rev Port Cardiol*. 2012; 31: 577-587.
9. Syed IS, Glockner JF, Feng D et al. Role of cardiac magnetic resonance imaging in the detection of cardiac amyloidosis. *JACC Cardiovasc Imaging*. 2010; 3: 155-164.
10. Rapezzi C, Quarta CC, Obici L, Perfetto F, Longhi S, Salvi F et al. Disease profile and differential diagnosis of hereditary transthyretin-related amyloidosis with exclusively cardiac phenotype: an Italian perspective. *Eur Heart J*. 2013; 34: 520-528.
11. Sorajja P, Ommen SR, Nishimura RA, Bernard J, Gersh, Peter B et al. Adverse prognosis of patients with hypertrophic cardiomyopathy who have epicardial coronary artery disease. *Circulation*. 2003; 108: 2342-2348.
12. Sadoul N, Prasad K, Elliott PM et al. Prospective prognostic assessment of blood pressure response during exercise in patients with hypertrophic cardiomyopathy. *Circulation*. 1997; 96: 2987-2991.
13. Barriales-Villa R, Centurion-Inda R, Fernandez-Fernandez X et al. Severe cardiac conduction disturbances and pacemaker implantation in patients with hypertrophic cardiomyopathy. *Rev Esp Cardiol*. 2010; 63: 985-988.
14. Spirito P, Autore C, Rapezzi C et al. Syncope and risk of sudden death in hypertrophic cardiomyopathy. *Circulation*. 2009; 119: 1703-1710.
15. Klues HG, Schiffers A, Maron BJ. Phenotypic spectrum and patterns of left ventricular hypertrophy in hypertrophic cardiomyopathy: morphologic observations and significance as assessed by two-dimensional echocardiography in 600 patients. *J Am Coll Cardiol*. 1995; 26: 1699-1708.
16. Guttman OP, Rahman MS, O'Mahony C, Anastasakis A, Elliott PM. Atrial fibrillation and thromboembolism in patients with hypertrophic cardiomyopathy: systematic review. *Heart*. 2014; 100(6): 465-72.
17. Faber L, Seggewiss H, Gleichmann U. Percutaneous transluminal septal myocardial ablation in hypertrophic obstructive cardiomyopathy: results with respect to intraprocedural myocardial contrast echocardiography. *Circulation*. 1998; 98: 241-2421.
18. Ten Cate FJ, Soliman OI, Michels M et al. Long-term outcome of alcohol septal ablation in patients with obstructive hypertrophic cardiomyopathy: a word of caution. *Circ Heart Fail*. 2010; 3: 362-369.
19. Durand E, Mousseaux E, Coste P et al. Non-surgical septal myocardial reduction by coil embolization for hypertrophic obstructive cardiomyopathy: early and 6 months follow-up. *Eur Heart J*. 2008; 29: 348-355.
20. Oto A, Aytemir K, Okutucu S et al. Cyanoacrylate for septal ablation in hypertrophic cardiomyopathy. *J Interv Cardiol*. 2011; 24: 77-84.
21. Lawrenz T, Borchert B, Leuner C et al. Endocardial radiofrequency ablation for hypertrophic obstructive cardiomyopathy: acute results and 6 months' follow-up in 19 patients. *J Am Coll Cardiol*. 2011; 57: 572-576.
22. Slade AK, Sadoul N, Shapiro L et al. DDD pacing in hypertrophic cardiomyopathy: a multicentre clinical experience. *Heart*. 1996; 75: 44-49.
23. Topilski I, Sherez J, Keren G, Copperman I. Long-term effects of dual-chamber pacing with periodic echocardiographic evaluation of optimal atrioventricular delay in patients with hypertrophic cardio-

myopathy .50 years of age. *Am J Cardiol.* 2006; 97: 1769-1775.

24. O'Mahony C, Jichi F, Pavlou M et al. A novel clinical risk prediction model for sudden cardiac death in hypertrophic cardiomyopathy (HCM Risk-SCD). *Eur Heart J.* 2013; doi: 10.1093/eurheartj/eh439.
25. Olivotto I, Girolami F, Ackerman MJ et al. Myofilament protein gene mutation screening and outcome of patients with hypertrophic cardiomyopathy. *Mayo Clin Proc.* 2008; 83: 630-638.