

Indazole Synthetic Cannabinoids Intoxication Associated with Fatal Cardiac Complications: Two Case Reports

Hakimian D^{1*}, Shapira B^{2,3}, Schallmach E⁴, Tepperberg M⁴, Berkovitz R², Buchman NM¹, Salameh S⁵ and Muszkat M¹

¹Department of Internal Medicine, Hebrew University Hadassah Medical, Center, Mt Scopus, Jerusalem, Israel

²Division of Enforcement and Inspection, Israel Ministry of Health

³Braun School of Public Health and Community Medicine, Hebrew University of Jerusalem, Israel

⁴Institute of Clinical Toxicology, SHEBA medical Center Tel Hashomer, Israel

⁵Department of Emergency Medicine, Hebrew University Hadassah Medical Center, Mt Scopus, Jerusalem, Israel

Volume 4 Issue 4- 2020

Received Date: 03 June 2020

Accepted Date: 16 June 2020

Published Date: 20 June 2020

1. Abstract

Usage of synthetic cannabinoids is associated with severe medical consequences and limited detectability in toxicology panels. We present two cases of patients with acute myocardial infarction resulting in death promptly after Indazole SC exposure demonstrating that AMI may be associated with consumption of SC and require greater awareness from physicians.

2. Key words

Synthetic Cannabinoids, Cardiotoxic, Lidocaine, Ventricular Fibrillation

3. Key Clinical Message: Consumption of indazole-based synthetic cannabinoids was cardiotoxic, resulting in death. When a patient in any age with suspected drug use presents with MI and arrhythmia, the clinician should also consider the involvement of synthetic cannabinoids

4. Abbreviations: Synthetic Cannabinoids (SC); Acute Myocardial Infarction (AMI); SC's cannabinoids receptor (CBR), δ 9-Tetrahydrocannabinol (THC), Supraventricular Tachycardia (SVT), Ventricular Fibrillation (VF), Cardiovascular Disease (CVD), Emergency Department (ED)

5. Background

Synthetic Cannabinoids (SC) are a prevalent, versatile and a constantly evolving group of novel psychoactive substances worldwide [1-5]. Their continued use represents a serious public health problem in Israel and throughout the world, despite the use of innovative and comprehensive legislation engineered to tackle this issue [6]. Synthetic cannabinoids are common illegal illicit drugs marketed as smokable herbal mixtures, and referred to by various names such as: "k-9", "Spice", "scooby doo" and "Mr nice guy" [4, 7].

These products carry the active synthetic substance, which is initially dissolved with acetone or similar solvents, and then directly sprayed on herbal products such as damiana, althea or tobacco, and smoked by the user using "joints", "bongs", liquids vaporizers or in e-cigarettes [7-9].

SC target cannabinoids receptor (CBR). CBR-1 and CBR-2 of which the CBR-1 exerts psychotropic effects [10-12] while CBR-2 is involved in the regulation of the immune system activity. In contrast to δ 9-Tetrahydrocannabinol (THC), synthetic cannabinoids are full rather than partial agonists of the CBR-1 and thus are more potent [5, 13, 14].

There is no single identifiable toxidrome related to consumption of SC [15]. The variable toxidromes may be due to combined drug intoxications and drug adulterants [16, 17]. Previous reports have placed an emphasis on central nervous system adverse effects such as agitation [18, 19] central nervous system depression [18, 19] psychosis, hallucinations [9, 18, 19] and hypertension, emesis, hypokalemia [8] and tachycardia [18]. Severe and fatal manifestations such as hemorrhagic stroke [20] acute kidney injury [21], seizures [22], acute mesenteric ischemia [22] and additional fatal cardiac manifestations, are also associated with SC use.

Indazole core based synthetic cannabinoids such as AB FUBINACA, ADB FUBINACA, are considered a newer generation of "ultrapotent" SC (Figure 1, 4). Their use is associated with rapid alteration of the mental status causing somnolence and "zombie" like appearance [24, 25] and can cause seizures and epilepsy [26, 27] acidosis [26] cardiac arrhythmia [27] and considered more potent and cardiotoxic than first generations of synthetic cannabinoids [8, 27, 28, 29].

Supraventricular tachycardia was described in a patient follow-

*Corresponding Author (s): David Hakimian, Department of Internal Medicine, Hadassah Hebrew University Medical Center Mount Scopus, Jerusalem, 91240 Israel, E-mail: davidh@hadassah.org.il

Citation: Hakimian D, Indazole Synthetic Cannabinoids Intoxication Associated with Fatal Cardiac Complications: Two Case Reports. Annals of Clinical and Medical Case Reports. 2020; 4(4): 1-6.

ing ingestion of e-cigarette fluid containing AB-FUBINACA and ADB-FUBINACA [27].

Another case report describes a 41-year-old, normally healthy individual, collapsing at home after smoking a cigarette containing the potent SC - ADB-FUBINACA. In post mortem autopsy, thrombotic occlusion of the lumen of the left anterior descending coronary artery was found, along with pulmonary edema and vascular congestion [29]. Another patient was admitted to the emergency department with inferior AMI after consuming potpourri of SCs containing the indazole active ingredient AMB-FUBINACA [30].

Besides the SC active ingredients described above causing the cardiotoxicity, adulterants such as lidocaine, benzocaine, as well as inert substances are sometimes intentionally added to bulk substances. Adulterants may dilute, complement, mimic or enhance the effects of SC [31]. These substances comprise an additional challenge in diagnosis and treatment of SC intoxication due to their unpredictable clinical consequences.

We present two cases of fatal cardiotoxicity associated with recreational use of illegal indazole-based SC.

6. Analytical Methods

Urine Samples were hydrolyzed (acid hydrolysis), extracted (liquid-liquid acid and basic extractions) and acetylated. Exhibit's samples were extracted in methanol. All samples were analyzed by Gas Chromatography-Mass Spectrometry (GC-MS) in unknown screening mode (Agilent 7890A) for unchanged SC compounds.

7. Clinical Presentation of Patients with Fatal Cardiac Complication

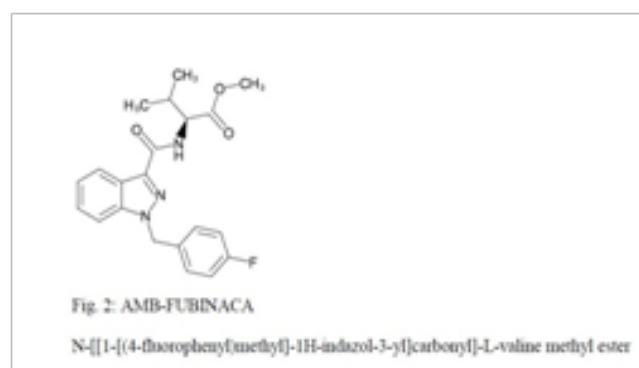
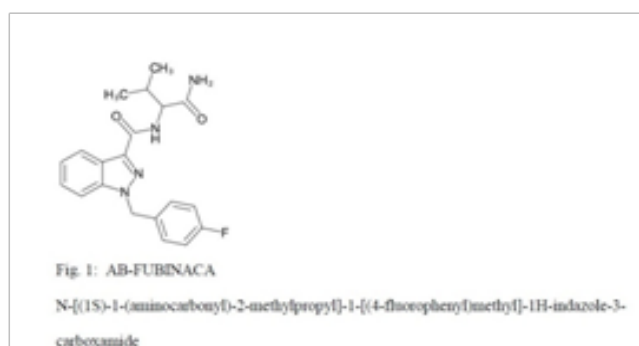
Both patients were males, aged 50 and 52 years, correspondingly. Neither patient had previous cardiovascular disorders or a major cardiovascular risk aside from smoking. Patients were not known drug abusers according to medical history and family. Both patients reported severe chest pain, which started approximately 30 to 60 minutes after smoking the SC ventricular fibrillation (VF) was observed in both patients (Table 1).

Features	Case 1	Case 2
Age (years)	50	52
Cardiovascular Risk	cigarette smoking	cigarette smoking
Interval after consuming SC	60 minutes	30 minutes
SC mixture street name	"Mr. Nice Guy"	"Mr. Nice Guy"
Arrhythmia	VF	VT / VF
Toxic screen urine immunoassay	Negative	Negative
GC-MS analysis	AB FUBINACA and Lidocaine (urine)	ADB FUBINACA, AMB -FUBINACA and 5f-ADB (smoked potpourri)
Abbreviations: Synthetic Cannabinoids (SC's), chromatography-mass spectrometry (GC-MS)		

7.1 Case 1

A 50-year-old male with no significant underlying medical conditions and without risk factors for ischemic heart disease and family

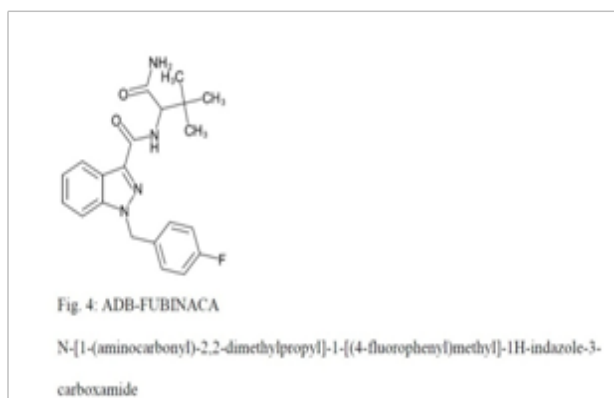
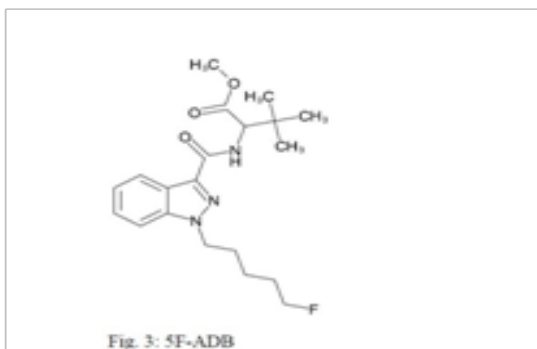
history of cardiovascular disease (CVD) was brought to the emergency department (ED) due to severe chest pain after smoking a synthetic cannabinoid marketed as "Mr. Nice Guy", and consumed as a smokable "joint". The patient smoked the SCs about one hour prior to arrival at the ED. He complained of chest pain before arriving at ED and collapsed upon entering the ED, presenting as pulseless VT. Cardiac pulmonary resuscitation (CPR) was promptly initiated and the patient was immediately intubated. Cardiac monitor demonstrated ventricular fibrillation (VF), Initial electrolyte profile was within normal ranges. The CPR included ten unsynchronized bi-phasic 200 joule electric shocks, intravenous (IV) 1 mg adrenaline, IV 300 mg amiodarone and IV calcium carbonate. The resuscitation effort lasted for 40 minutes while the patient rhythm turned from VF to pulseless electrical activity (PEA) and eventually he demised. Toxic screen urine immunoassay was negative for the presence of amphetamines and cocaine. Post mortem dissection was suggested to the family; however, they declined. Patient's urine sample was sent for analysis with gas chromatography-mass spectrometry (GC-MS) in general unknown screening mode. Results showed the presence of AB FUBINACA and the anesthetic lidocaine (Figure 1).



7.2. Case 2

A 52-year-old male patient was brought to the emergency room unconscious, and not breathing. Past medical history included cigarette smoking, without other relevant medical history and family history of CVD. The patient's family reported that he smoked "Mr. Nice guy" as a "joint" half-an-hour before his arrival. After smoking the SCs he complained of severe chest pain, radiating to

the left arm following which he collapsed. Emergent intubation was performed upon his presentation at once with CPR. Cardiac monitor demonstrated VT and VF. The CPR included unsynchronized bi-phasic 200 joule electric shocks, 3 doses of intravenous (IV) 1 mg adrenaline, IV 300 mg amiodarone and IV magnesium 2 mg. After 20 minutes of CPR the patient had signs of Return of Spontaneous Circulation (ROSC) and was hemodynamically stable, without need for vasopressors support. However, he was not responding with dilated pupils and was admitted to the cardiac intensive care unit. Laboratory tests included 0.27 ng/ml troponin T levels (0-0.03 ng/ml) and 2121 U/L creatine phosphokinase (39-308 U/L), initial electrolyte levels were within normalthe normal range. He underwent echocardiogram indicating diffuse motion abnormality of the left ventricle reflecting the cardiac severe injury by ischemia. During his hospitalization he was diagnosed with subarachnoid hemorrhage following the appearance of seizures. Subsequently, he was treated with antiepileptics and did not have any indication for neurosurgical intervention as the hemorrhage was stable. . Four days after this reported ingestion of the SC. the patient developed bradycardia and asystole, and later demised after developing bradycardia and asystole. On the patient's arrival to ED urine tests were sent for standard toxic screen immunoassay which was negative. The patient's family provided us with the herbal material he smoked which was analyzed using GC-MS. The analysis identified ADB FUNINACA, AMB -FUBINACA and 5f-ADB in the mixture (Figure 4,2,3).



8. Discussion

While synthetic cannabinoids with an indazole core have appeared in the drug market as early as 2013, substances such as FUB-AMB, 5F-ADB and ADB-FUBINACA have only been recently controlled in schedule I of the Controlled substance act). AB-FUBINACA was permanently placed in scheduled I in September 2016. Indazole-carboxamides, such as 5F-ADB and ADB-FUBINACA and their derivatives were scheduled in the Israeli drug ordinance as early as April 2014 [32].

In the cardiovascular system, cannabinoid receptors are located on the myocardium, vascular endothelial and smooth muscle cells, as well as circulating blood cells. CBR-1 are also present in the peripheral nervous system, including vagal afferent neurons [33] and thus may affect cardiovascular responses on various levels. The activation of cardiovascular CBR-1 signaling may result in endothelial dysfunction, pro-inflammatory effects, increase oxidative stress, and myocardial cell death [33].

The exact function of CBR-1 is unknown, but several studies have shown the receptors relevance to cardiovascular function and health. In one study CBR-1 blockade in mice reduced plaque development and cholesterol levels [34]. In healthy persons, CBR1 recept or lead to changes such as bradycardia, tachycardia, hypotension and arrhythmias on the usage of SC [35]. CBR-2 receptors have apparently a cardioprotective role by limiting inflammation and injury in many cardiovascular disease [35].

The two patients presented in these reports had clinical manifestations of AMI (suggested by acute tight chest pain radiating to the left arm) and ventricular arrhythmia complicating AMI. The clinical presentation taking place shortly after smoking SC supports the assumption of a relationship between SC consumption and cardiac manifestations including fatal cardiac arrhythmia. The association between the use of the cannabis plant, containing the active cannabinoid THC and AMI was first described in 1979 [36]. Dozens of cases of AMI associated with marijuana usage have been reported since. These reports usually involve marijuana smoking by young patients with normal coronary arteries. It was suggested that the risk for AMI increases 4.8 -fold one hour after consumption of marijuana and decreases to 1.7 times between 1 to 2 hours after consumption [37].

The connection between AMI to SC is less established, some researchers postulated that similar high proportion of AMI with marijuana is also demonstrated with SC consumption [35]. AMI involvement with indazole compounds usage reports is lower than other SC. Only a few cases of proven fatal cardiac toxicity involving the use of newer indazole and indazole-based SC that have been analytically confirmed have been previously reported. However, these reports, along with the one presented here suggest that cardiac complications should become more common as these compounds of increased potency and popularity continue circulating

in the drug market [35].

In one of our patients, lidocaine was identified in the herbal mixture provided by the family of the deceased. We assumed that lidocaine had been mixed with the SC as it was neither used in resuscitation in the ER nor pre-hospitalization. Lidocaine is a well-known adulterant of inhaled drugs such as cocaine [36, 37] due to its easy absorption on mucus membranes and nasal mucosa and pain numbing properties [38, 39]. Serum levels above 10 mcg/mL are considered extremely toxic and are associated with convulsions, respiratory arrest, coma and cardiovascular collapse [40]. The primary cardiovascular side effects of lidocaine include reduced cardiac contractility, vasodilatation, sinus rhythm slowing, QRS widening, hypotension, shock, asystole, atrioventricular block and ventricular arrhythmias [41, 42]. Lidocaine has been detected in smoke condensates after pyrolysis of freebase cocaine [43], though it is questionable if at effective levels. Hence, it is unlikely that smoking lidocaine contributed to the descendant's death, as cardiotoxicity is considered an adverse effect of high serum concentrations achieved through I.V or S.C administration of lidocaine [40], which are doubtful to have been achieved by SC smoking

Our two cases demonstrate that fatal cardiovascular manifestations can be associated with a variety of indazole compounds that may not be detected by standard urine toxic screen. Furthermore, in nearly all the case reports and studies of fatal cardiovascular manifestations following cannabinoid consumption, patients were adolescences and young adults [21, 24, 27, 29]. Our cases present two men at their fifties, with history of smoking, demonstrating that SC's severe cardiovascular intoxication should be in adults. A high level of suspicion warrants further toxicological analysis, in addition to the use of standard immunoassay kits for all common substances. The combinations of indole and indazole based-compounds in one mixture, which resulted in the patient's death is also exceptional, and might have contributed to increased cardiac toxicity.

9. Conclusions

Cases suggest that clinicians should consider the possibility of synthetic cannabinoid toxicity in scenarios involving patients of all ages, and of all health statuses presenting to the ED with AMI or unexplained life-threatening arrhythmia, and despite negative bedside immunoassay screening for recreational drug. Patients should be aware that consumption of synthetic cannabinoids can be fatal and be avoided.

Reference

1. Kemp AM, Clark MS, Dobbs T, Galli R, Sherman J, Cox R. Top 10 Facts You Need to Know About Synthetic Cannabinoids: Not So Nice Spice. *Am J Med* 2016; 129: 240-244.e1.
2. European Monitoring Centre for Drugs and Drug Addiction. Euro-

pean Drug Report 2018: Trends and Developments. Luxembourg: Publications Office of the European Union; 2018.

3. White CM. The Pharmacologic and Clinical Effects of Illicit Synthetic Cannabinoids. *J Clin Pharmacol* 2017; 57: 297–304. doi:10.1002/jcph.827.
4. Tournebize J, Gibaja V, Kahn J-P. Acute effects of synthetic cannabinoids: update 2015. *Subst Abus* 2017; 38: 344-366.
5. Van Hout MC, Hearne E. User Experiences of Development of Dependence on the Synthetic Cannabinoids, 5f-AKB48 and 5F-PB-22, and Subsequent Withdrawal Syndromes. *Int J Ment Health Addict* 2017; 15: 565-79. doi:10.1007/s11469-016-9650-x.
6. Marta Rychert et al., "Are Government-Approved Products Containing New Psychoactive Substances Perceived to Be Safer and More Socially Acceptable than Alcohol, Tobacco and Illegal Drugs? Findings from a Survey of Police Arrestees in New Zealand: Health Perceptions of Government-Approved NPS in NZ," *Drug and Alcohol Review*, December 29, 2017; 37(3): 406-413
7. Brents LK, Prather PL. The K2/Spice Phenomenon: emergence, identification, legislation and metabolic characterization of synthetic cannabinoids in herbal incense products. *Drug Metab Rev.* 2014; 46(1): 72-85. doi:10.3109/03602532.2013.839700.
8. Cohen J, Morrison S, Greenberg J, Saidinejad M. Clinical Presentation of Intoxication Due to Synthetic Cannabinoids. *Pediatrics.* 2012; 129(4): e1064-e1067. doi:10.1542/peds.2011-1797.
9. Hermanns-Clausen M, Kneisel S, Szabo B, Auwärter V. Acute toxicity due to the confirmed consumption of synthetic cannabinoids: clinical and laboratory findings. *Addiction.* 2013; 108(3): 534-544. doi:10.1111/j.1360-0443.2012.04078
10. Riederer AM, Campleman SL, Carlson RG, et al. Acute Poisonings from Synthetic Cannabinoids - 50 U.S. Toxicology Investigators Consortium Registry Sites, 2010-2015. *MMWR Morb Mortal Wkly Rep.* 2016; 65(27): 692-5. doi:10.15585/mmwr.mm6527a2.
11. Grotenhermen F. Pharmacology of cannabinoids. *Neuro Endocrinol Lett.* 25(1-2):14-23.
12. Huffman JW, Padgett LW. Recent developments in the medicinal chemistry of cannabimimetic indoles, pyrroles and indenenes. *Curr Med Chem.* 2005; 12(12): 1395-411.
13. Pertwee RG. Targeting the endocannabinoid system with cannabinoid receptor agonists: pharmacological strategies and therapeutic possibilities. *Philos Trans R Soc Lond B Biol Sci.* 2012; 367(1607): 3353-63. doi:10.1098/rstb.2011.0381.
14. Le Boisselier R, Alexandre J, Lelong-Boulouard V & Debruyne D. Focus on cannabinoids and synthetic cannabinoids. *Clinical Pharmacology & Therapeutics.* 2017; 101(2): 220-229.
15. Gurney SMR, Scott KS, Kacinko SL, Presley BC, Logan BK. Pharmacology, Toxicology, and Adverse Effects of Synthetic Cannabinoid

- Drugs. *Forensic Sci Rev.* 2014;26(1):53-78.
16. Fujita Y, Koeda A, Fujino Y, et al. Clinical and toxicological findings of acute intoxication with synthetic cannabinoids and cathinones. *Acute Medicine & Surgery.* 2016 Jul; 3(3): 230-236. DOI: 10.1002/ams2.18
 17. Barbera N, Busardò FP, Indorato F, Romano G. The pathogenetic role of adulterants in 5 cases of drug addicts with a fatal outcome. *Forensic Sci Int.* 2013; 227(1-3): 74-76. doi:10.1016/j.forsciint.2012.08.041.
 18. Shanks KG, Dahn T, Behonick G & Terrell A. Analysis of first and second generation legal highs for synthetic cannabinoids and synthetic stimulants by ultra-performance liquid chromatography and time of flight mass spectrometry. *Journal of analytical toxicology.* 2012; 36(6): 360-371.
 19. Adamowicz P, Gieron J. Acute intoxication of four individuals following use of the synthetic cannabinoid MAB-CHMINACA. *Clinical Toxicology* 2016; 54: 650-4. doi:10.1080/15563650.2016.1190016.
 20. Hermanns-Clausen M, Müller D, Kithinji J, Angerer V, Franz F, Eyer F, et al. Acute side effects after consumption of the new synthetic cannabinoids AB-CHMINACA and MDMB-CHMICA. *Clin Toxicol* 2018; 56: 404-11. doi:10.1080/15563650.2017.1393082.
 21. Rose DZ, Guerrero WR, Mokin MV, Gooch CL, Bozeman AC, Pearson JM & Burgin WS. Hemorrhagic stroke following use of the synthetic marijuana “spice”. *Neurology*, 2015; 85(13): 1177-1179.
 22. Tait RJ, Caldicott D, Mountain D, Hill SL, & Lenton S. A systematic review of adverse events arising from the use of synthetic cannabinoids and their associated treatment. *Clinical toxicology*, 2016; 54(1), 1-13.
 23. Tofighi, Babak, and Joshua D. Lee. “Internet highs-seizures after consumption of synthetic cannabinoids purchased online.” *Journal of addiction medicine.* 2012; 6(3): 240-241.
 24. Hakimian D, Tomer O, Hiller N, Heyman SN, & Israel S. Fatal mesenteric ischemia induced by synthetic cannabinoids: a case report and literature review. *Case reports in emergency medicine*, 2017. 2017:6964078. doi: 10.1155/2017/6964078.
 25. Adams AJ, Banister SD, Irizarry L, Trecki J, Schwartz M, Geron R. “Zombie” Outbreak Caused by the Synthetic Cannabinoid AMB-FUBINACA in New York. *N Engl J Med.* 2017; 376(3): 235-242. doi:10.1056/NEJMoa1610300.
 26. Klavž J, Gorenjak M, Marinšek M. Suicide attempt with a mix of synthetic cannabinoids and synthetic cathinones: Case report of non-fatal intoxication with AB-CHMINACA, AB-FUBINACA, alpha-PHP, alpha-PVP and 4-CMC. *Forensic Sci Int.* 2016; 265: 121-124. doi:10.1016/j.forsciint.2016.01.018.
 27. Brenneman R, Papsun D, Logan B & Neavyn M. A Death-Like Slumber Toxic Outbreak of AB-FUBINACA. *J Med Toxicol.* 2016; (12(1)): 3-47.
 28. Boland DM, Reidy LJ, Seither JM, Radtke JM & Lew EO. Forty-Three Fatalities Involving the Synthetic Cannabinoid, 5-Fluoro-ADB: Forensic Pathology and Toxicology Implications. *Journal of forensic sciences*, 2020; 65(1), 170-182.
 29. Lam RPK, Tang MHY, Leung SC, Chong YK, Tsui MSH, Mak TWL. Supraventricular tachycardia and acute confusion following ingestion of e-cigarette fluid containing AB-FUBINACA and ADB-FUBINACA: a case report with quantitative analysis of serum drug concentrations. *Clin Toxicol.* 2017; 55(7): 662-667. doi:10.1080/15563650.2017.1307385.
 30. Gamage, Thomas F, et al. “Molecular and behavioral pharmacological characterization of abused synthetic cannabinoids MMB-and MDMB-FUBINACA, MN-18, NNEI, CUMYL-PICA, and 5-Fluoro-CUMYL-PICA.” *Journal of Pharmacology and Experimental Therapeutics* 2018; 365(2): 437-446.
 31. Shanks KG, Clark W, Behonick G. Death Associated With the Use of the Synthetic Cannabinoid ADB-FUBINACA. *J Anal Toxicol.* 2016; 40(3): 236-9. doi:10.1093/jat/bkv142.
 32. Hamilton RJ, Keyfes V, Banka SS. Synthetic Cannabinoid Abuse Resulting in ST-Segment Elevation Myocardial Infarction Requiring Percutaneous Coronary Intervention. *J Emerg Med.* 2017; 52(4): 496-498. doi:10.1016/j.jemermed.2016.09.023.
 33. Cole C, Jones L, McVeigh J, Kicman A, Syed Q, & Bellis M. Adulterants in illicit drugs: a review of empirical evidence. *Drug testing and analysis* 2011; 3(2); 1-48.
 34. Pacher P, Steffens S, Haskó G, Schindler TH, Kunos G. Cardiovascular effects of marijuana and synthetic cannabinoids: the good, the bad, and the ugly. *Nat Rev Cardiol.* 2017; 15(3): 151-166.
 35. Sugamura K, Sugiyama S, Fujiwara Y, et al. Cannabinoid 1 receptor blockade reduces atherosclerosis with enhances reverse cholesterol transport. *J Atheroscler Thromb.* 2010; 17(2): 141-7.
 36. Ozturk HM, Yetkin E Ozturk S. Synthetic cannabinoids and cardiac arrhythmia risk: Review of the literature. *Cardiovascular toxicology*, 2019; 19(3): 191-197.
 37. Bachs L, Mørland H. Acute cardiovascular fatalities following cannabis use. *Forensic Sci Int.* 2001; 124(2-3): 200-3.
 38. Mittleman MA, Lewis RA, Maclure M, Sherwood JB, Muller JE. Triggering myocardial infarction by marijuana. *Circulation.* 2001; 103(23): 2805-9.
 39. Cruz A, López-Rivadulla M, Bermejo AM, Sánchez I, Fernández P. Sequential Second Derivative Spectroscopy of Cocaine and Adulterants in Street Drug Samples. Part I: Cocaine, Procaine, and Lidocaine. *Anal Lett.* 1994; 27(14): 2663-2675. doi:10.1080/00032719408005998.
 40. Fucci N, De Giovanni N. Adulterants encountered in the illicit cocaine market. *Forensic Sci Int.* 1998; 95(3): 247-52. doi:10.1016/

S0379-0738(98)00102-9.

41. Shannon M. Clinical toxicity of cocaine adulterants. *Ann Emerg Med.* 1988; 17(11): 1243-7.
42. Van Dyke C, Jatlow P, Ungerer J, Barash P, Byck R. Cocaine and lidocaine have similar psychological effects after intranasal application. *Life Sci.* 1979; 24(3): 271-274. doi:10.1016/0024-3205(79)90229-7.
43. Schwartz DR, Kaufman B. Local Anesthetics. *Emergency Medicine.* 1163.
44. Hoffman RS, Howland MA, Lewin NA, Nelson LS, Goldfrank LR, eds. *Goldfrank's Toxicologic Emergencies, 10e.* New York, NY: McGraw-Hill Education; 2015.
45. Mather LE, Chang DH. Cardiotoxicity with modern local anaesthetics: is there a safer choice? *Drugs.* 2001; 61(3): 333-42.
46. Moore PA, Hersh E V. Local Anesthetics: Pharmacology and Toxicity. *Dent Clin North Am.* 2010; 54(4): 587-599. doi:10.1016/j.cden.2010.06.015.
47. Pawlik E, Mahler H. Smoke analysis of adulterated illicit drug preparations. *ToxicheKrimtech.* 2001; 78: 200-10.