

# Eumycotic Mycetoma (Madura's Foot), Case Report and Literature Review

Hussam AlHarbi H<sup>1\*</sup>, Ahmed Al-Shehri A<sup>1</sup> and Bandar Idrees Ali BI<sup>1</sup>

<sup>1</sup>Department of Surgery, Prince Sultan Military Medical City, Riyadh, Kingdom of Saudi Arabia

Volume 4 Issue 7- 2020

Received Date: 15 July 2020

Accepted Date: 27 July 2020

Published Date: 30 July 2020

## 2. Key words

Madura foot; Mycetoma; Fungal Infection

## 1. Abstract

Madura foot is a rare disease in our country caused by chronic infections either bacterial or fungal organisms that involve skin and underlying soft-tissue of the foot, The diagnosis is made by clinical picture, microscopic examination confirmed by special stains or culture. We describe a case of a 47 years old male medically free with a history of left foot swelling for 6 months. Ultrasound of left foot was done and showed Isoechoic oval shaped mass lesion on the superficial planter fascia compatible planter fibromatosis. Mass resection was done. The histopathological findings were eumycetoma with positive special stains highlight fungal hyphae.

## 3. Introduction

Madura foot is a chronic infection of the skin and underlying tissues caused by both bacteria (actinomycotic mycetoma or actinomycetomas) and fungi (eumycetomas or mycotic mycetoma) [1]. The name of the disease came from an Indian town of Madura that first case was described in 1842 [7]. The infection is endemic in Africa, India, and South America. Some cases have also been reported in local people or migrants in temperate countries, including some European countries [3]. It is a chronic infection of the cutaneous and subcutaneous tissue [7].

## 4. Case Report

This is a 47 years old Saudi male medically free referred from Orthopaedics to General surgery clinic with chief complaints of swelling of the left foot for 6 months. The patient was normal till 6 months back then he felt discomfort in the left foot mainly during walking long distance. He notices a mass in the sole of the left foot too at the same time. Not increasing in the size and no history of discharge. No history of the same complaint before with no family history of the same condition. The patient was seen initially in the Primary Health Care clinic with the same complaint and referred to orthopaedic. He is X-smoker he was smoking for 20 years then he quit smoking 4 years prior to noticing the mass. He is non-alcoholic. He is a military and never travel outside Saudi Arabia. He has Camels and he used to go to his Camels on his own farm for the last 10 years almost every weekend. He used to walk off-shoes sometimes on the farm. The patient could not recall a 'starting event' or episode of trauma associated with the mass. On examination, the patient was overweight not in pain walking no gait abnormality. Vitally stable. On cutaneous examination, he has a swelling 3x4 cm

in the left plantar aspect of the foot. Not painful. It is hard with no fluctuation. Regular shape not attached to the skin but fixed to the underlying tissues. Not pulsatile and no skin changes. No clinical signs of infection (erythema, heat, purulence). There were no lymphatic streaks or palpable inguinal adenopathy. No scar, skin break or lower limb edema. No history of fever or weight loss. Neurovascular bundle intact peripherally. Labs were ordered and were all within normal ranges.

X-ray left foot done reported as mild metatarsophalangeal joint arthrosis, No focal bony lesion. Soft tissue assessment by X-ray is limited (Figure 1).

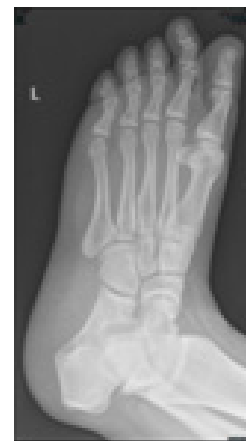

Figure1: X-ray left foot done reported as mild metatarsophalangeal joint arthrosis, No focal bony lesion. Soft tissue assessment by X-ray is limited.

Ultrasound of left foot showed Isoechoic oval shaped mass lesions measuring 1.6 x 0.7 cm based on the superficial planter fascia medial aspect with thickening of the underlying fascia without increased vascularity in keeping with planter fibromatosis (Figure 2).

\*Corresponding Author (s): Hussam Al-Harbi, Department of Surgery, Prince Sultan Military Medical City Riyadh Saudi Arabia., Tele: 0591026789, E-mail: aaaalharbi@psmmc.med.sa

Citation: Hussam AlHarbi H. Eumycotic Mycetoma (Madura's Foot), Case Report and Literature Review. Annals of Clinical and Medical Case Reports. 2020; 4(7): 1-3.

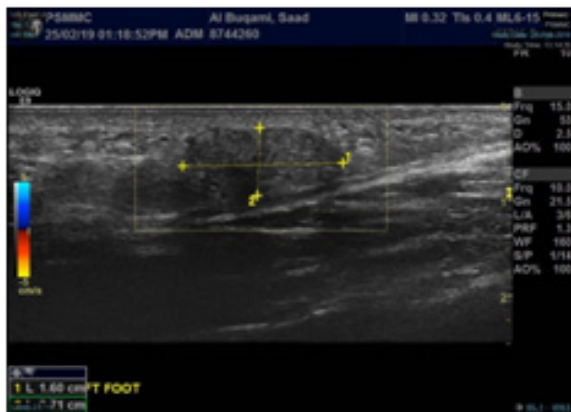
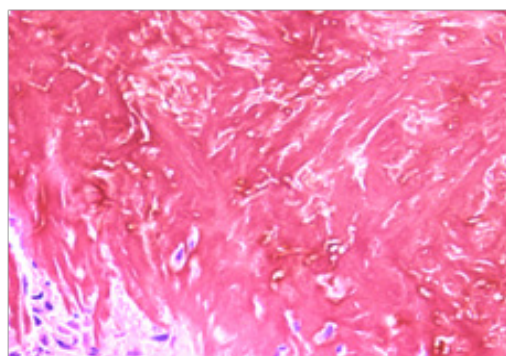
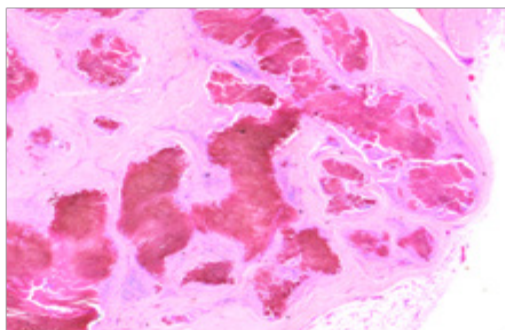


Figure 2: Ultrasound of left foot showed Isoechoic oval shaped mass lesions measuring 1.6 x 0.7 cm based on the superficial planter fascia medial aspect with thickening of the underlying fascia without increased vascularity in keeping with planter fibromatosis.

Patient was booked for excisional biopsy as Day Case and he was operated under regional block (ankle block) to the left lower extremity and an elliptical incision was made on the plantar aspect centrally to the mass. A 2 cm x 1 cm x 0.5 cm dark brown to black firm heterogeneous mass with calcification was excised from the plantar aspect. After good irrigation skin closed primarily. Antibiotics with instructions for daily dressing and follow-up after 2 weeks.



Figures 3A and 3B: H&E stained sections showing well circumscribed nodule consist of densely matted branched and septated hyphae with budding spores embedded in collagen like material surrounding by mixed inflammatory cells.

Histopathology findings were of H&E stained sections showing well circumscribed nodule consist of densely matted branched and septated hyphae with budding spores embedded in collagen like material surrounding by mixed inflammatory cells (Figures 3A and 3B).

Special stains for GMS and PAS highlight fungal hyphae confirming the diagnosis of eumycetoma (Figures 4 and 5).

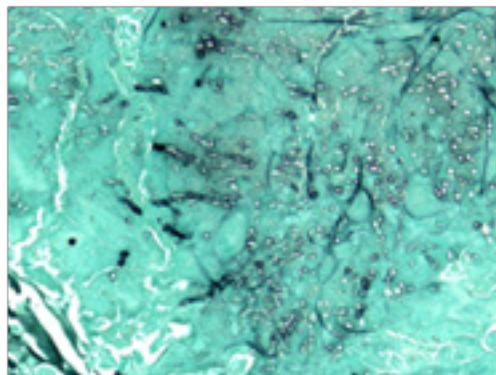


Figure 4: Special stain for GMS highlight fungal hyphae confirming the diagnosis of eumycetoma.

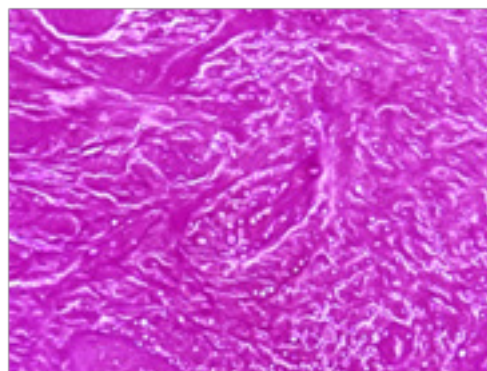


Figure 5: Special stain for PAS highlight fungal hyphae confirming the diagnosis of eumycetoma.

The patient was seen in the clinic, the wound was clean healed no discharges and no signs or symptoms of infection. Sutures were removed. Infectious Disease team was contacted, and he was referred to them. Now he is on Fluconazole 400 mg BID With regular follow-up with Infectious Disease team.

## 5. Discussion

Mycetoma is a specific chronic, granulomatous, inflammatory disease. caused by true fungi or by higher bacteria of the class actinomycetes and hence it is classified as eumycetoma or actinomycetoma [2]. It is predominantly a disease of tropical or subtropical countries, commonly seen in countries between 30°N and 15°S of the equator, but some cases have also been seen in Saudi Arabia, Europe, and USA [3].

It usually involves the subcutaneous tissue. It has a prolonged, progressive, and indolent course, and, if untreated, it might lead to the destruction of the deeper tissues and bone, resulting in deformity and amputation in severe cases affected parts with all the social and economic implications of this.

Characteristic for mycetoma is that, upon entering the human body, the causative agents organize themselves in granules called grains. These grains are probably formed as a defense mechanism against the human immune system [3].

These grains can be differentiated by color, size, and consistency, based on the causative microorganism. Generally, the fungus forms black or white grains, while bacteria have more colour such as red, yellow and white [3].

So far, more than 56 different microorganisms recognized to cause mycetoma, the most prevalent causative agent of eumycetoma worldwide, and in Africa in particular, is the fungus *M. mycetomatis*.<sup>9,10</sup> For example, in Sudan *M. mycetomatis* causes more than 70% of all mycetoma infections [4]. The incidence, prevalence, and route of transmission are not well understood, due to lack of information and it is not a reportable disease.

Mycetoma occurs most often in people who work in rural areas, usually in farmers and hunter-gatherer populations. mainly found in young adults [3]. In most countries, males are more often infected than females. Although most cases are found in this age group, no age is exempted [3].

Lower extremities involvement is more common. Mycetoma involving the foot is called “Madura foot” and it accounts for 68.7% of mycetoma cases. Fungi are involved as causative agents of mycetoma (Eumycetoma) and *Madurella mycetomatis* is the most common causative agent [5]. The clinical correlate of both forms of mycetoma is tumescence with abscesses, painless nodules, sinuses and discharge. The latter is commonly serous-purulent and contains grains (filamentous granules) which can be expressed for diagnostic purposes [6].The recommended treatment is itraconazole 200-400 mg/ day for 6-9 months, in combination with surgery if necessary [5].

The radiological findings of Madura foot are not specific in X-ray and computed tomography scans (CT). Magnetic resonance imaging (MRI) points out the soft tissue and joint and bone involvement, allowing classification of the severity of the infection.

The differential diagnosis includes infectious (tuberculosis, fungal or bacterial infections) and non-infectious skin diseases (bone or soft tissue cancer) [5].

## References

1. Jindal A, Patel LM, Singh A. Clinical Picture: Madura Foot. *Indian J Surg* 80. 2018; 627–628.
2. Naoufal Hjira, Adil Boudhas, Abderrahmane AlBouzidi, Mohammed Bouia. Madura foot: Report of a eumycetoma Moroccan case. 2015; 19(2): 143-145.
3. Hala Taha Mohamed, Ahmed Fahal, Wendy WJ van de Sande. Mycetoma: epidemiology, treatment challenges, and progress, *Research and Reports in Tropical Medicine* 2015: 6.
4. Fraser M, Borman AM, Johnson EM. Rapid and robust identification of the agents of black-grain mycetoma by MALDI-ToF mass spectrometry. *Journal of Clinical Microbiology*. 2017; 55(8): 2521-2528.
5. Wendy WJ, van de Sande, Ahmed H Fahal, Michael Goodfellow, El Sheikh Mahgoub, Oliverio Welsh, Ed E. Zijlstra . Merits and Pitfalls of Currently Used Diagnostic Tools in Mycetoma. *PLoS Negl Trop Dis*. 2014; 8(7): e2918.
6. Jessica Mencarini, Alberto Antonelli, Guido Scoccianti, Laura Bartolini, Giuliana Roselli etc al. Madura foot in Europe: diagnosis of an autochthonous case by molecular approach and review of the literature *New Microbiologica*, 2016; 39(2): 156-159.
7. Nenoff P, van de Sande WW, Fahal AH, Reinel D, Schöfer H. Eumycetoma and actinomycetoma--an update on causative agents, epidemiology, pathogenesis, diagnostics and therapy, *The Journal of the European Academy of Dermatology and Venereology*. 2015; 29(10): 1873-83.