

Intestinal Cystic Pneumatosis : Rare Case

Abdelhak B^{*}, Said B¹, Moutaoukil M¹, Hakim K¹, Bouchentouf SM¹, Mountacer M¹ and Bounaim A¹

¹Department of Visceral Surgery, MVMIH, Rabat, Morocco

Volume 4 Issue 8- 2020

Received Date: 30 July 2020

Accepted Date: 17 Aug 2020

Published Date: 21 Aug 2020

2. Key words

Intestinal pneumatosis; Idiopathic pneumoperitoneum; Small bowel movements

1. Abstract

Intestinal cystic pneumatosis is a rare condition characterized by the presence of gaseous cysts in the intestinal wall.

We report the observation of a 51-year-old patient with dyspepsia syndrome and recurrent episodes of abdominal pain who had a three-day cessation of materials and gas for three days. The clinical examination on admission showed a slightly distended abdomen, an empty rectal bulb with digital rectal examination. The biological assessment was without abnormality, the radiography of the abdomen without preparation showed central hydro-aeric levels of the hail-like type with a gaseous crescent inter hepato-diaphragmatic. The abdominal CT objectified a pneumoperitoneum with aerobilia, an upper digestive distension with probable proximal digestive volvulus. The patient was admitted to the block and an exploratory laparotomy was performed which revealed the presence of a gas cyst in several places in the small intestine with distension of the latter upstream of a large mass of benign appearance. Taking a segment of the jejunum. We carried out an anastomosis resection of the small intestine carrying out the mass which we sent to the pathological anatomy laboratory and the result of which returned in favor of intestinal cystic pneumatosis. The postoperative suites were simple with good evolution and resumption of transit at end of the third day.

Intestinal cystic pneumatosis is rare and generally mild. In 85% of cases, it is secondary or associated with other gastrointestinal pathologies (inflammatory bowel disease, peptic ulcer, pyloric stenosis, abdominal trauma) or extra gastrointestinal (chronic obstructive pulmonary disease, heart disease, cystic fibrosis, lupus , knotty peri-arthritis); Primitive forms represent only 15% of reported cases. In our patient we concluded with a primary intestinal cystic pneumatosis. Most authors report non-specific signs. Some complications related to cystic volume have been described, they are rare but require resection. This is the case of our patient whose intestinal cystic pneumatosis was responsible for the volvulus of a segment of the small intestine which induced an occlusive syndrome. Cystic intestinal pneumatosis is the leading cause of pneumoperitoneum without digestive perforation. Computed tomography with injection of contrast agent has good diagnostic accuracy. There is an important diagnostic criterion, which is the lack of airport that differentiates it from intestinal gangrene. The treatment of uncomplicated intestinal cystic pneumatosis is most often medical, the aim of which is to reduce the anaerobic bacteria which is at the origin, metronidazole is often effective. Hyperbaric oxygen therapy is used for its anti-anaerobic power and for its ability to collapse cysts by promoting exchanges with the blood. Other therapies such as octreotide or endoscopic fenestrations have been used with varying results. In the forms complicated or resistant to medical treatment, the treatment is surgical and consists in resecting the affected intestinal segment, by laparotomy or better by laparoscopy given the benign nature of the pathology, this is the case of our patient who benefited from emblematic of a resection of the mass and anastomosis of the small intestine.

Intestinal cystic pneumatosis is a rare and generally mild condition. Its diagnosis is most often made on imaging, especially the abdominal computed tomography with injection of contrast product. Its treatment remains medical for the benign forms whereas it is surgical for the complicated forms preferably by laparoscopic approaches.

**Corresponding Author (s): Abdelhak Bensal, Department of Visceral Surgery, Mohamed V-Rabat Military Instruction Hospital, Morocco Tele: 00212661292229, Email: abdelbensal@gmail.com*

Citation: Abdelhak B. Intestinal Cystic Pneumatosis : Rare Case. Annals of Clinical and Medical Case Reports. 2020; 4(8): 1-3.

3. Introduction

Intestinal cystic pneumatosis is a rare affection characterized by the presence of gas cysts in the intestinal wall, it can reach the entire digestive tract with a predilection for the small intestine. It is a generally mild pathology. If the cyst ruptures, it can release air into the peritoneal cavity and cause pneumoperitoneum.

4. Materials and Methods

We report the observation of Mr. M.D, aged 51, with a history of dyspepsia syndrome and recurrent episodes of abdominal pain, who presented with a stop of materials and gases for three days. The clinical examination at admission objectified a patient in good general condition, non-pyretic, slightly distended abdomen without defense or contracture, rectal bulb empty with rectal examination. The biological assessment, in particular a blood count and a complete ionogram, was without abnormality, the radiography of the abdomen without preparation showed central hydro-aeric levels of the hail type with a gaseous crescent inter hepato-diaphragmatic. The abdominal CT objectified a pneumoperitoneum with aerobilia, an upper digestive distension with probable proximal digestive volvulus. The patient was admitted to the block after his condition: two peripheral venous tracts, nasogastric tube and urinary tube, an exploratory laparotomy was performed which highlighted the presence of gas cyst in several places in the small intestine with distension of the latter upstream of a large mass of benign appearance taking a segment of the jejunum. We performed an anastomosis resection of this mass which we sent to the pathological anatomy laboratory and the result returned in favor of intestinal cystic pneumatosis. The postoperative follow-ups were simple with good evolution and resumption of transit at the end of the third day. The patient was discharged six days after admission and was seen regularly for consultation (Figure 1 and 2).

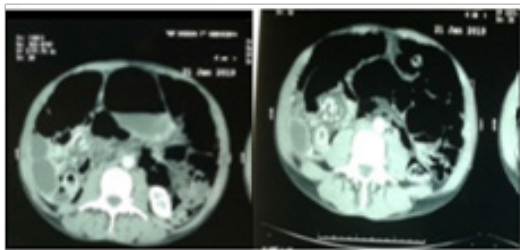


Figure 1: CT images of our patient showing small bowel volvulus with intestinal distention and upstream.

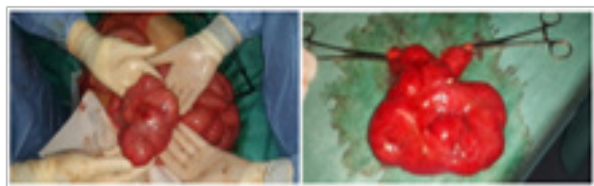

Figure 2: Hail mass before and after resection.

5. Results

Intestinal cystic pneumatosis is rare and generally mild [1, 2]. In 85% of cases, it is secondary or associated with other gastrointestinal pathologies (inflammatory bowel disease, peptic ulcer, pyloric stenosis, abdominal trauma) or extra gastrointestinal (chronic obstructive pulmonary disease, heart disease, cystic fibrosis, lupus, knotty peri-arthritis); Primitive forms represent only 15% of reported cases. In our patient we concluded with a primary intestinal cystic pneumatosis. Intestinal cystic pneumatosis is generally pauci-symptomatic [3]. Most authors report non-specific signs in 30% of cases: vomiting, diarrhea, constipation, etc. Abdominal meteorism is found in 38% of cases. Certain complications related to cystic volume have been described: intussusception, volvulus, perforation [4]. They are rare but require resection [4]. This is the case of our patient whose intestinal cystic pneumatosis was responsible for the volvulus of a segment of the small intestine which induced an occlusive syndrome. Cystic intestinal pneumatosis is the leading cause of pneumoperitoneum without digestive perforation [5, 6] and radiography of the abdomen without preparation often shows pneumoperitoneum due to ruptures of the sub-serous cysts in the peritoneal cavity [5, 7]. with contrast agent injection has good diagnostic accuracy [8] by highlighting images of gas density in the digestive wall [9, 10]. The association with an asymptomatic pneumoperitoneum is pathognomonic [3]. There is an important diagnostic criterion, which is the lack of airport that differentiates it from intestinal gangrene [11]. In endoscopy, the cysts correspond to large hemispherical sessile polyps covered with a pale and transparent mucous membrane, sometimes ulcerated, not performed in our patient. Typically, a sagging cyst is obtained at puncture or biopsy with a bursting noise. [12] The treatment of uncomplicated intestinal cystic pneumatosis is most often medical, the aim of which is to reduce the anaerobic bacteria which metronidazole is often found to be effective [6, 7]. Hyperbaric oxygen therapy is used for its anti-anaerobic power and for its ability to collapse cysts by promoting exchanges with the blood [6, 7]. Other therapies such as octreotide or endoscopic fenestrations have been used with varying results [6]. In the forms complicated or resistant to medical treatment, the treatment is surgical and consists in resecting the affected intestinal segment, by laparotomy or better by laparoscopy considering the benign nature of the pathology [6, 13], this is the case of our patient who immediately benefited from an anastomosis after resection.

6. Conclusion

Intestinal cystic pneumatosis is a rare and generally mild condition. Its diagnosis is most often made on imaging, especially the abdominal computed tomography with injection of contrast prod-

uct. Its treatment remains medical for the benign forms whereas it is surgical for the complicated forms preferably by laparoscopic approaches.

References

1. Heng Y, MD Schuffler, RC Haggitt, CA Rohmann. Pneumatosis intestinalis: a review. *Am J Gastroenterol.* 1995; 90(10): 1747-58.
2. Grasland A, J Pouchot, J Leport, J Barge, P Vinceneux. Pneumatosis cystoides intestinalis. *Press Med.* 1998; 27(35): 1804-12
3. Jamart J. Pneumatosis cystoides intestinalis –A statistical study of 919 cases. *Acta Hepatogastroenterol (stuttgart).* 1979; 26(5): 419-22
4. Meikel G. A case of pneumatosis coli: pneumatosis cystoides intestinalis of the sigmoid colon causing intestinal obstruction, stercoral ulcer and perforation. *J R Coll Surg Edinb.* 1965; 11(1): 65-7.
5. Quintart C, C Choghari, D Michez, P Lefebvre, B Ramdani. Intestinal cystoid pneumonia- Diagnostic elements and therapeutic approach. *Ann Chir.* 1997; 51(9): 1032-5.
6. Boland C, T de Ronde, M Lacrosse, JP Trigaux, L Delaunois, M Melange. Pneumatosis cystoides intestinalis associated with steinert disease. *Gastroenterol Clin Biol.* 1995; 19(3): 305-8.
7. Estermann F, B Denis, P Gaucher, D Regent, D Sondag. Pneumatosis cystoides of the colon: knowing how to recognize it- Apropos of 8 cases. *Ann Gastroenterol Hepatol.* 1994; 30(4): 151-5.
8. Pun YL, DM Russell, GJ Taggart, DR Barraclough. Pneumatosis intestinalis and pneumoperitoneum complicating mixed connective tissue disease. *Br J Rheumatol.* 1991; 30(2): 146-9.
9. Scheidler J, A Stabler, G Kleber, D Neidhardt. Computed tomography in pneumatosis intestinalis: differential diagnosis and therapeutic consequences. *Abdom Imaging.* 1995; 20(6): 523-8.
10. Brientini F, M Debilly, JF Litzler, G Raclot, A Le Mouel. Colonic cystic pneumatosis - A specific x-ray computed tomographic diagnosis: apropos of 2 cases. *J Radiol.* 1995; 76(2-3): 135-40.
11. Feczko PJ, DG Mezwa, MC Farah, BD White. Clinical significance of pneumatosis of the bowel wall. *Radiographic.* 1992; 12 (6): 1069-78.
12. Rogy MA, DF Mirza, E Kovats, R Rauhs. Pneumatosis cystoides intestinalis (PCI). *Int J Colorectal Dis.* 1990; 5(2): 120-4.
13. Boerner RM, DB Fried, DM Warshauer, K Isaacs. Pneumatosis intestinalis - two case reports and a retrospective review of the literature from 1985 to 1995. *Dig Dis Sci.* 1996; 41(11): 2272-85.