

## Fiberoptic Bronchoscopic Treatment of Gastric Aspiration in a Patient with Chest Stomach Ectopia a Case Report

Wang L<sup>1\*#</sup>, Dai Z<sup>1\*#</sup> and Zhang Z<sup>1#</sup>

<sup>1</sup>Department of Anesthesiology, Shenzhen People's Hospital (The First Affiliated Hospital, Southern University of Science and Technology; The Second Clinical Medical College, Jinan University), Shenzhen Engineering Research Center of Anesthesiology, Shenzhen, Guangdong 518020, P.R. China

### \*Corresponding author:

Zhongliang Dai,  
Zhongjun Zhang, Department of Anesthesiology,  
Shenzhen People's Hospital (The First Affiliated  
Hospital, Southern University of Science and  
Technology; The Second Clinical Medical  
College, Jinan University), Shenzhen  
Engineering Research Center of Anesthesiology,  
Shenzhen, Guangdong 518020, P.R. China,  
E-  
mail: daizhongliang@jnu.edu.cn, lu

Received: 05 Oct 2021

Accepted: 19 Oct 2021

Published: 23 Oct 2021

### Copyright:

©2021 Dai Z, Zhang Z. This is an open access article distributed under the terms of the Creative Commons Attribution License, which permits unrestricted use, distribution, and build upon your work non-commercially.

### Citation:

Dai Z, Zhang Z, Fiberoptic Bronchoscopic Treatment of Gastric Aspiration in a Patient with Chest Stomach Ectopia a Case Report. *Ann Clin Med Case Rep.* 2021; V7(12): 1-5

### Keywords:

Gastric aspiration; Mendelson's syndrome; Fiberoptic bronchoscopy; Mask positive ventilation

### Abbreviations:

ER: Emergency Room; FOB: Fiberoptic Bronchoscope; ICU: Intensive Care Unit; CT: Computed Tomography; PACU: Post-Anesthesia Care Unit; OR: Operation Room

### #Author Contribution:

Wang L, Dai Z, Zhang Z, These authors are contributed to equally to this work

## 1. Abstract

Patients who received esophageal resection and gastro-esophageal rebuild before was likely to occur stomach-ectopia to chest when years later. Patients who occurred gastric aspiration during anesthesia have very high risks proceeding to severe aspiration pneumonia or Mendelson's syndrome. A 67-year-old female patient had a history of esophageal carcinoma 10 years ago, then she received a radical esophageal resection and gastro-esophageal rebuild. In a new operation with sufficient fasting period, the patient aspirated the gastric contents during anesthesia induction, about 20 minutes later after a low tidal mask positive ventilation. The patient was diagnosed as gastric aspiration from fiberoptic bronchoscopy revealing yellow and green gastric contents existed in her airway. Visually intra-tracheobronchial suction and irrigation with sterile saline was performed through the fiberoptic bronchoscope to remove the gastric contents. Though receiving FOB intervention as

late as nearly 5-hours after aspiration, the patient still recovered very well without secondary intubation or other complications. Careful and comprehensive pre-operative visit was vital to anesthesiologists. Patients with a history of esophageal surgery should avoid mask positive ventilation during anesthesia induction. Fiberoptic bronchoscopy guided suction and irrigation was a very effective and powerful method to treat gastric contents aspiration.

## 2. Introduction

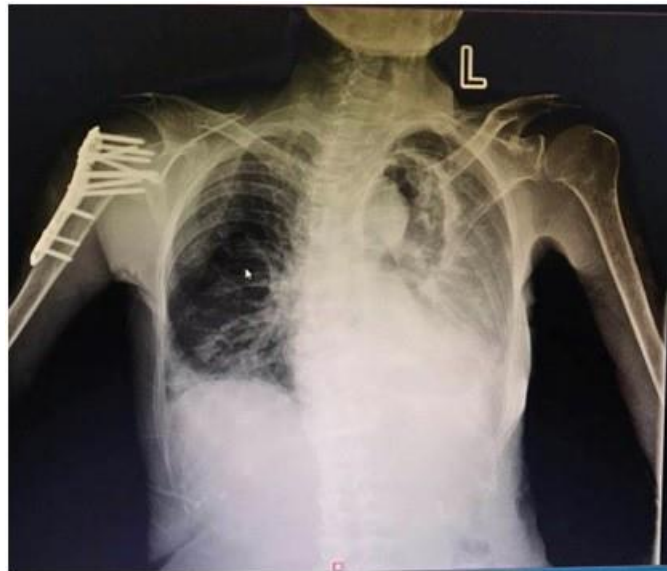Perioperative airway management can be challenging in patients with a history of gastrointestinal surgery. Patients who received gastrointestinal or esophageal surgery before is vulnerable to aspiration especially during anesthesia intubation and extubation periods [1, 2]. In particular, the acid gastric contents aspiration is especially a disaster compared with other kinds of aspiration, known as Mendelson's syndrome [3]. The conventional treatment of Mendelson's syndrome were anti-infection, anti-fibrosis, hor-

monotherapy and ventilator support therapy [4]. Previously, the treatments to gastric aspiration were really limited and helpless, leading to high mortality and bad outcomes [5]. But after Fiberoptic Bronchoscopy (FOB) was applied to aspiration related pneumonia, it has been proved very effective in emergency ward, ICU, and cerebral surgery departments [6,7,8]. But in anesthesiology, as far as we know, it still has not been suggested as a guideline or the first choice to aspiration during anesthesia [9]. Here we reported this efficient treatment to Mendelson's syndrome, and our case showed that even FOB was not applied immediately, it still had benefit compared with other traditional methods. Furthermore, we dig out the lessons from the preoperative visit to anesthesia induction, and it warned us that the junior resident anesthesiologists should be more cautious.

### 3. Case Report

A 67-year-old female patient had an esophageal carcinoma 10 years ago, and she received a radical esophageal resection and

gastroesophageal rebuild then. Since then she recovered very well, and only remained the impaired appetite and the weight loss. In her lifetime she had no symptoms of reflux or flatulence. This time she suffered from a traffic crash and was submitted to hospital. She was diagnosed as multiple fractures, postoperative esophageal cancer, mild anemia, hyperglycemia, moderate malnutrition, hypoproteinemia. At first, she received a surgery on humerus and tibiofibular in ER, and stepped into a temporary stable condition. One week later, she was submitted to OR for a fixation of femoral neck fracture again. This time she had enough fasting period before operation. The day before the second surgery when the primary resident anesthesiologist executed the preoperative visit, the thoracic CT examination was not in her document and the resident only checked the thoracic X-ray, ECG assessment, CT examination around hip joint, and some other basic blood examinations. The thoracic X-ray report was bilateral pleural effusion and pulmonary infection, as shown in (Figure 1).



**Figure 1:** Chest X-ray taken before operation: the left pleural effusion is more than before. Some pleural effusion on the right side, some infiltration on the lower right lung.

On the morning of the second surgery, she was in good condition when she came into OR. After enough sedation, the anesthesiologists gave her a conventional induction, that is, sequentially injection of fentanyl, propofol, cisatracurium, sufentanil, and then gave her a low tidal and high frequency positive mask ventilation (300 ml volume, 16 times per minute. Height: 153 cm, weight: 40 kg). About 3 minutes later after drug administration, the doctor started to intubate. But immediately after opening her mouth, some yellow and green liquid flowed out. Urgent suction was executed in mouth and then intubation was finished immediately. Before connecting to ventilator, bronchial suction through tracheal catheter was also executed seriously. During the induction period and the first 1 hour

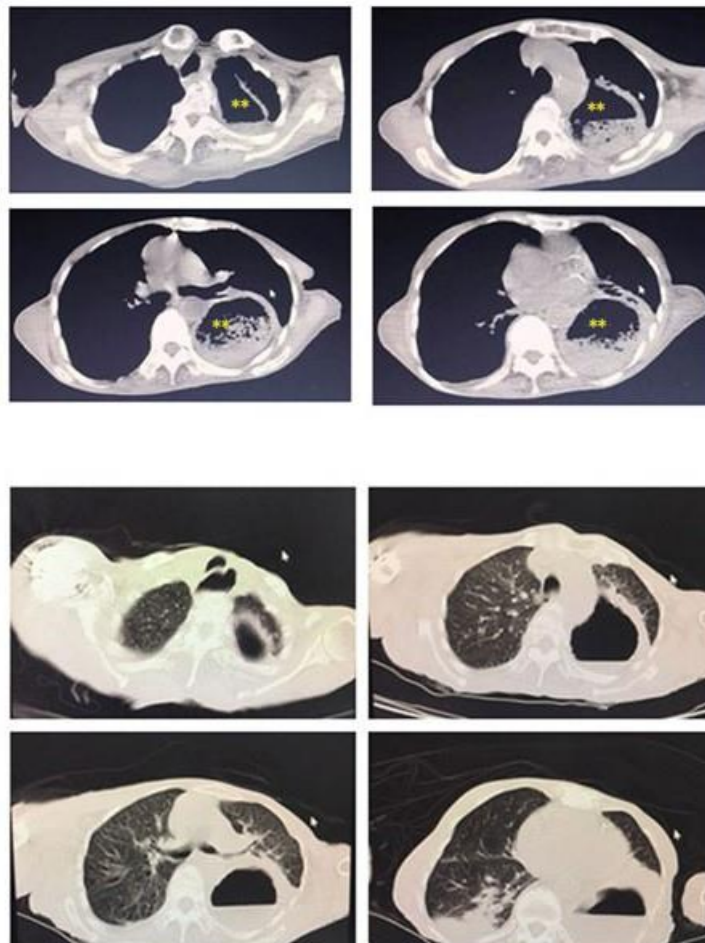
after induction, SpO<sub>2</sub> was 100% with 50% FiO<sub>2</sub>, and the bilateral pulmonary auscultation was normal.

But in the following time, abnormal symptoms started to arise. We need to rise FiO<sub>2</sub> gradually to reach the 100% SpO<sub>2</sub>. The wheezing started to appear, slight at first, and then became more and more obvious in the following 2 hours. The surgery lasted about 3 hours. At the end of the surgery, increasing FiO<sub>2</sub> to 70% could maintain the patient's vital signs to normal including heart rate, SpO<sub>2</sub> and blood pressure. Methylprednisolone and aminophylline were administered during the surgery. After she was transferred to PACU, the heart rate started to increase gradually. 20 minutes later in PACU, she revived well with a high heart beat about 110 bpm.

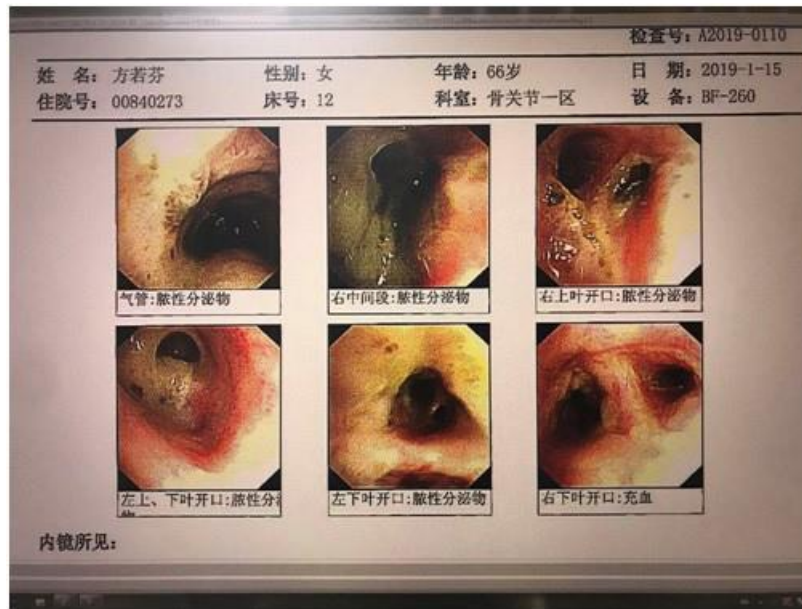
After extubation, she had very obvious difficulty and shortness in breath and couldn't get rid of the high-flow oxygen supply (6-8L/min) through the mask, and her thoracic movement was very fierce. The lung wheezing rale became more and more obvious. Then she was transferred to respiratory department for a Fiberoptic Bronchoscopy examination (FOB).

When she arrived the respiratory department, 5 hours had passed since the aspiration. Before FOB examination, the respiratory doctor searched the patient's thoracic CT examination from the hospital network, founding that the patient's stomach was absolutely stayed in chest and had expanded a lot, as shown in (Figure 2). Fentanyl and midazolam were given and a good cooperation was achieved. Then FOB was inserted into the bronchus and bronchi. Some green and yellow purulent secretion were found covering the bronchus and bronchi, as shown in Figure 3. Then FOB guided

suction and irrigation in every segmental bronchus were performed carefully to remove the mucus and residue. Immediately after the operation, the patient said she felt better, with her thoracic cups and downs, respiratory rate, and heart rate were all decreased to normal obviously. Then she was transferred to ICU for further treatment. During her stay in ICU for 2 days, she received the conventional treatments including hormone therapy, aminophylline, salbutamol and arterial blood gas analysis and so on. Her arterial blood gas analysis was always below the standard of mechanical assistant ventilation (as shown in Table 1), so she just received the nasal oxygen supply (2-4L/min) without intubation. At the third day in ICU, she refused to receive invasive arterial blood gas analysis and demanded returning to the general ward, so the orthopedist took her out of ICU. In general ward, she received some antibiotics and recovered very well, 10 days later she was discharged from hospital without any complications.



**Figure 2:** Chest computed tomography (CT) performed before operation: the thoracic stomach is on the left, stomach was absolutely in left thorax. Some scattered exudation existed on the basal segments of bilateral lower lung lobes. Some pleural effusion existed on the bilateral side. Arrows showed the expanded thoracic stomach at different levels. Figure 2a is from pulmonary window and Figure 2b is from CT mediastinal window.



**Figure 3:** Bronchoscopy pictures taken after aspiration: much yellow-green purulent secretion existed in the opening of bronchus of many lobes and segments.

**Table1:** Arterial blood gas analysis after aspiration

	90mins after aspiration	**6h after aspiration	24h after aspiration	48h after aspiration
<b>PH</b>	7.331	7.302	7.399	7.391
<b>pO<sub>2</sub>(mmHg)</b>	92.2	82.5	90.3	93.3
<b>pO<sub>2</sub>(mmHg)</b>	37.4	32.1	37.3	44.8
<b>Oxygen flow(L/min)</b>	/	4	4	4
<b>Calculated FiO<sub>2</sub></b>	77%	37%	37%	37%
<b>Oxygenation index</b>	119.74	222.97	244.05	252.16
<b>SpO<sub>2</sub></b>	96%	95%	96%	99%

#### 4. Discussion

For those patients who have occurred aspiration, no matter the aspiration contents were blood, gastric juice, bile or disinfectant, the fiberoptic bronchoscopy suction and irrigation treatment is always effective [6, 7, 8]. This has been demonstrated in ER and neurological ICU where there were high risks of aspiration. But in MODERN anesthesia (version IV), it advocated that if gastric aspiration was plenty, bronchus irrigation may lead to acid corrosion spreading, so FOB guided irrigation and suction was not suggested as the first aid. We thought this proposition should be thought twice. A blind irrigation without FOB guide through tracheal tube may cause corrosion or infection spreading, because without instant and thorough suction, the acid fluid may flow around. But the new developed respiratory FOB apparatus can switch irrigation and suction promptly, so the spreading fluid can be limited very well. So we suggest that FOB guided suction and irrigation therapy could be the first choice for aspiration, even for the acid aspiration.

For those patients who had gastrointestinal surgery before, it

should be cautious that they were very vulnerable to aspiration especially during induction in anesthesia. According to the A&E Clinical Guidelines No. 14 Guidelines on Rapid Sequence Intubation (RSI), it is strongly suggested that these kinds of patients should apply RSI [10, 11]. The main points of RSI include enough pre-oxygen, rapid sequential drug administration, pressing cricoid cartilage, and avoid positive pressure ventilation before capsule inflation. Our junior resident had two mistakes: firstly he didn't realize that the woman had a history of esophagus resection which may lead to high risks of aspiration during induction; secondly he gave the woman a mask positive pressure ventilation, which should be avoided according to RSI in A&E Clinical Guidelines. The positive mask ventilation may inflate the woman's residual stomach and increase the aspiration risks.

For the anesthesiologists, it should be cautious when executing the pre-operation visit. Careful and comprehensive history-taking and examinations-screening are very important. For those patients who received a history of esophagus excision and stomach-esophagus reconstruction, it is worth noting that there is a build-up of stomach in chest

would expand as time goes on [12]. The thoracic CT examination is vital to this kind of patients and superior to X-rays. Just as in our case, thoracic X-ray was not sensitive to recognize the stomach expanding, only diagnosing the bilateral pleural effusion. But in the later thoracic CT examinations, the diagnosis was an expanded residual stomach absolutely stayed in chest, which should have indicated a very high risk of aspiration. In the department discussion after surgery, with a more careful observation, we found an image of expanded residual stomach beside the aorta in the thoracic X-ray, as shown in Figure 1. Our junior anesthesiologist missed the thoracic CT examination and only checked the X-ray, so he missed a very important point during history-taking.

For the chairmen of anesthesiology department, we suggest that they build a strong relationship with the respiratory department. In our hospital, after this case, the chairmen in anesthesiology and respiratory department built a green channel of aspiration related FOB treatment, aiming at the aspiration cases during anesthesia.

Thanks for this cooperation, recently we had saved another obstetric aspiration during induction.

In conclusion, we suggest the FOB guided irrigation and suction recommended for those who has occurred aspiration during anesthesia. Patients who had a history of esophagus reconstruction surgery or other gastrointestinal surgery should apply RSI induction and avoid mask positive ventilation. During history-taking procedure, it should be more careful and cautious. Our patient had a very good prognosis due to a timely and efficient intervention, which may be a useful case for other anesthesiologists.

## 5. Funding

This study was supported by the Shenzhen Key Medical Discipline Construction Fund (grant no. SZXK044) and Shenzhen's Sanming Project of Medicine (grant no. SZSM202011021).

## References

1. Robinson M, Davidson A. Aspiration under anaesthesia: risk assessment and decision-making [J]. *Continuing Education in Anaesthesia Critical Care & Pain*. 2014; 14: 171-5.
2. Olsson GL, Hallen B, Hambræus-Jonzon K. Aspiration during anaesthesia: a computer-aided study of 185,358 anaesthetics. *Acta Anaesthesiol Scand*. 1986; 30: 84-92.
3. Mendelson CL. The aspiration of stomach contents into the lungs during obstetric anesthesia. *Am J Obstet Gynecol*. 1946; 52: 191-205.
4. Gibbs CP, Modell JH. Pulmonary aspiration of gastric contents: pathophysiology, prevention, and management. In: Miller RD, editor. *Miller's Anesthesia*. 4th ed. New York: Churchill Livingstone; 1994; 1437-64.
5. Abdulla S. Pulmonary aspiration in perioperative medicine. *Acta Anaesthesiol Belg*. 2013; 64: 1-3.
6. Ryu T, Kim DH, Byun SH. Fiberoptic bronchoscopic treatment of blood aspiration and use of sugammadex in a patient with epistaxis: A case report [J]. *Medicine*, 2018; 97: e0428.
7. An TH, Ahn BR. Pneumonia due to aspiration of povidone iodine after induction of general anesthesia - A case report - [J]. *Korean Journal of Anesthesiology*. 2011; 6.
8. Choi SH, Lee SJ, Yoon KB, Han S, Kim JH. Fiberoptic bronchoscopic treatment of pulmonary aspiration occurring in a child during induction of anesthesia - A case report. *Korean J Anesthesiol*. 2005; 49: 744-7.
9. Gal TJ. Airway management. In: Miller RD, editor. *Miller's Anesthesia*. 6th ed. New York: Elsevier Churchill Livingstone; 2005; 1617-52.
10. Smith, Charles E. Rapid-Sequence Intubation in Adults: Indications and Concerns [J]. *Clinical Pulmonary Medicine*. 2001; 8: 147-65.
11. CBL, Wong A & E. *Clinical Guidelines No. 14 Guidelines on Rapid Sequence Intubation (RSI)*
12. Konradsson M, Nilsson M. Delayed emptying of the gastric conduit after esophagectomy. *J Thorac Dis*. 2019; 11: S835-44.