

Concomitant Diseases in a Complex Case of Peritonitis after Stapled Trans Anal Rectal Resection (Starr) in Obstructed Defecation Syndrome (Ods). Role of a Diagnostic and Therapeutic Multidisciplinary Approach

Guarino E^{1*} and Passantino DG²

¹Department of General Surgery, University of Camerino, Italy

²Department of General Surgery, Sapienza - University of Rome, Italy

*Corresponding author:

Enrico Guarino,
University of Camerino, Italy,
E-mail: dr.enricoguarino@gmail.com

Received: 22 Dec 2021

Accepted: 11 Jan 2022

Published: 18 Jan 2022

J Short Name: ACMCR

Copyright:

©2022 Guarino E. This is an open access article distributed under the terms of the Creative Commons Attribution License, which permits unrestricted use, distribution, and build upon your work non-commercially.

Citation:

Guarino E, Concomitant Diseases in a Complex Case of Peritonitis after Stapled Trans Anal Rectal Resection (Starr) in Obstructed Defecation Syndrome (Ods). Role of a Diagnostic and Therapeutic Multidisciplinary Approach. *Ann Clin Med Case Rep.* 2022; V8(6): 1-3

1. Abstract

Approximately 0.06-2.3% of the population presents a Jejunal and Ileal Diverticular (JID) disease, of whom approximately 10% develop life-threatening complications such as inflammation, perforation, bleeding, obstruction, and malabsorption [1-3, 9]. Although only 40% of these patients remain asymptomatic, jejunal diverticulosis is usually not clinically suspected. The diagnosis of this condition is usually made incidentally or after the onset of complications as hemorrhage, diverticulitis, or obstruction. We report the case of a 45-year-old patient that presented, after a Stapled Trans Anal Rectal Resection (STARR) for an Obstructed Defecation Syndrome (ODS), a not related acute abdominal pain syndrome. In such complicated clinical cases has been mandatory to have a multidisciplinary approach.

2. Case Report

We visited a 45-years-old man with a diagnosis of ODS for rectal prolapse and anemia for a 3rd degree bleeding hemorrhoidal nodule. In anamnesis, the patient reported a diagnosis of sigmoid diverticulosis. After routine preoperative exams, the patient was treated to a rectal prolapsectomy with stapled trans-anal rectal resection (STARR) and submucosal hemorrhoidectomy.

The postoperative recovery was not complicated, and the patient was discharged on the second day after surgery in good clinical conditions, without fever, and with antibiotic therapy.

On the 4th day after surgery, the patient returned to the hospital

<http://acmcase reports.com>

with no specific acute abdominal pain. At the new recovery, the patient didn't have a fever, and the white blood cells were normal.

The clinical observation at the admission didn't show a peritoneal syndrome or a positive Blumberg sign neither. According to the anamnesis, we suspected an acute diverticulitis syndrome, and we decided to continue the antibiotic therapy.

Two days after, the patient presented fever and abdominal pain in the right pelvic area; the Blumberg sign became positive. The blood values showed a slight increase of white blood cells (12.5) and a worsening of the anemia (HB 8.5, HCT 21%).

According to the new clinical conditions, we decided to make an abdominal CT scan that showed free air under the right diaphragm but didn't show free liquid in the abdomen (Figure 1); the mechanical rectal suture was complete, and the CT scan didn't show free air in the mesorectal and pelvic area (Figure 2).

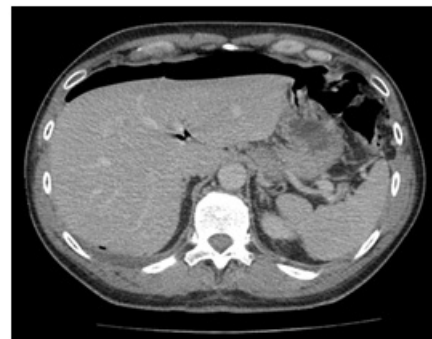

Figure 1: CT scan that shows free air under the right diaphragm without other signs of JID perforation.

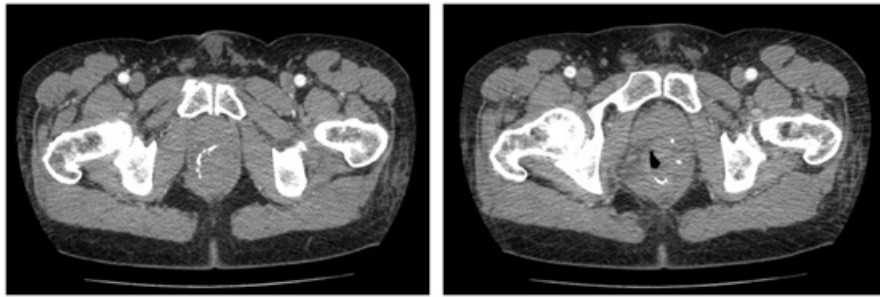


Figure 2: CT scan shows the absence of free air in the mesorectal and pelvic area and the integrity of the suture.

We decided to perform an exploratory laparoscopy that didn't present abnormality in the left side of the abdomen or signs of left diverticular perforation but showed the presence of an abscess in the right paracolic gutter. Considering the abscess and the ileo-peritoneal adhesions, we decided to perform laparotomy access with an enlarged McBurney incision. We found a retrocecal no-perforated appendicitis, the tip of which was fixed at the ileus, 20 cm to the ileocecal valve, close to perforation.

We made a regular appendectomy, closed the ileus hole, did an abdominal washing, and then was positioned drainage in the right paracolic gutter.

On the first postoperative day, the patient was in good general conditions without pain and fever; the blood analysis values were in the Range. On the third postoperative day, the patient had a regular bowel transit.

On the fifth postoperative day, the patient had a high fever (39.5°), leukocytosis (19.000) with neutrophilia (89%), low hemoglobin (7.5, HCT, 21%), and the bowel transit was blocked. Free air persisted in the upper part of the abdomen at the control CT scan, without free fluid; simultaneously, bilateral pleural effusion was found.

Under the infectious disease specialist (IDS), we started a triple antibiotic therapy with metronidazole, ciprofloxacin, and meropenem; before starting the antibiotic treatment, we performed a blood culture with a negative result.

The day after, the patient presented fever and frontal headache; anamnesis had reported an episode of frontal sinusitis almost seven months before, for which he necessitated a hospitalization.

So was performed a rhinoscopy that was positive for multidrug-resistant *Streptococcus Pneumoniae*; the antibiotic therapy was not modified but was added betamethasone in aerosol and intravenous. A few hours later, the patient didn't present fever, and he remained afebrile for the next 24 hours.

On the ninth day after surgery, the patient presented fever again (39°C), with white blood cells and PCR increased. The IDS, in consideration of the pleural effusion and the abdominal distension, advised continuing the therapy with the antibiotic association and the betamethasone.

The patient was afebrile for the next 72 hours, so he was discharged. <http://acmcasereports.com>

charged in good clinical conditions with an antibiotic and corticosteroid home therapy.

The histological exam showed appendicitis with serosal and not mucosal inflammation, such as the inflammation was coming from the peritoneum and not from the appendix.

3. Discussion

JID represents 18% of all small bowel diverticula, but they are most likely to become symptomatic in a patient's lifetime compared to other small bowel diverticula [4, 5].

Although the true etiology of jejunal diverticula is unknown, this condition is believed to develop from a combination of intestinal motility disorders, focal weakness of the muscularis, and high segmental intra-luminal pressures [6, 7].

These patients exhibit a constellation of symptoms that range from early satiety, bloating, chronic upper abdominal discomfort, and vague abdominal pain to a syndrome of bloating, steatorrhea, and malabsorption [8].

The diagnosis of a perforated diverticulum is rarely made preoperatively; in the emergency setting, abdominal CT is the modality of choice with findings that include thickening or inflammation of the jejunum and mesentery, localized abscess formation, air-fluid collection in contiguity with SB loops, free peritoneal air, and occasionally visualization of the diverticulum [10, 11].

This case report is an example of a delayed diagnosis due to a rare condition as the simultaneous presence of two different and not related surgical diseases in a young adult patient without other risks; in these cases, a delayed diagnosis could make the prognosis worse [3, 4, 12].

This patient had just been operated on with a STARR technique for an Obstructed Defecation Syndrome, so he took analgesic and antibiotic therapy, which hid the symptoms and delayed the accurate diagnosis; moreover, the anamnesis of diverticular disease moved the attention on acute diverticular inflammation.

Our patient, relying on the operation and especially on the histological examination, had a Jejunoileal Diverticulum (JID) that has perforated itself and created localized peritonitis close to the appendix, a clinical presentation like common appendicitis.

In this case, the exploratory laparoscopy was resolute because the CT scan didn't show the real side of the bowel perforation.

In our case, another element of confusion for the diagnosis was the intermittent fever, which was probably caused by the association of peritonitis, frontal sinusitis, and pleural effusion, with the presence of multidrug-resistant bacteria, so this inflammatory syndrome needed an association of antibiotic and cortisone therapy to get out.

4. Conclusion

This case is an example of a rare and under-diagnosed condition that may require immediate surgical intervention. In general, we recommend approaching a new clinical case considering the operation he did before and considering the possibility of a different diagnosis not related to the previous condition.

Diagnosis before surgical intervention may now be substantially aided by modern imaging modalities, particularly Computed Tomography (CT) [13]. However, we report, as in the literature [14-16], that sometimes an exploratory laparoscopy is better to show the actual damage and to perform a resolutive operation.

References

- Natarajan K, Phansalkar M, Varghese RG, Thangiah G. Jejunal diverticulosis with perforation – a challenging differential diagnosis of acute abdomen: case report. *J. Clin. Diagn. Res. JCDR.* 2015; 9: Ed03-4.
- Palder SB, Frey CB. Jejunal diverticulosis. *Arch. Surg. (Chic. Ill.* 1960) 1988; 123: 889-94.
- Longo WE, Vernava AM. 3rd Clinical implications of jejunoileal diverticular disease. *Dis. Colon Rectum.* 1992; 35: 381-8.
- Makris K, Tsiotos GG, Stafyla V, Sakorafas GH. Small intestinal non-meckelian diverticulosis. *J. Clin. Gastroenterol.* 2009; 43: 201-7.
- Akhrass R, Yaffe MB, Fischer C, Ponsky J, Shuck JM. Small-bowel diverticulosis: perceptions and reality. *J. Am. Coll. Surg.* 1997; 184: 383-8.
- Kassir R, Boueil-Bourlier A, Baccot S. Jejuno-ileal diverticulitis: etiopathogenicity, diagnosis and management. *Int. J. Surg. Case Rep.* 2015; 10: 151-3.
- Kongara KR, Soffer EE. Intestinal motility in small bowel diverticulosis: a case report and review of the literature. *J. Clin. Gastroenterol.* 2000; 30: 84-6.
- Patel VA, Jefferis H, Spiegelberg B, Iqbal Q, Prabhudesai A, Harris S. Jejunal diverticulosis is not always a silent spectator: a report of 4 cases and review of the literature. *World J. Gastroenterol. WJG.* 2008; 14: 5916-9.
- Kassahun WT, Fangmann J, Harms J, Bartels M, Hauss J. Complicated small-bowel diverticulosis: a case report and review of the literature. *World J. Gastroenterol. WJG.* 2007; 13: 2240-2.
- Mansoori B, Delaney CP, Willis JE. Magnetic resonance enterography/enteroclysis in acquired small bowel diverticulitis and small bowel diverticulosis. *Eur. Radiol.* 2015
- De Peuter B, Box I, Vanheste R, Dymarkowski S. Small-bowel diverticulosis: imaging findings and review of three cases. *Gastroenterol. Res. Pract.* 2009; 2009: 549853.
- De Bree E, Grammatikakis J, Christodoulakis M, Tsiftsis D. The clinical significance of acquired jejunoileal diverticula. *Am. J. Gastroenterol.* 1998; 93: 2523-8.
- Singh JP, Steward MJ, Booth TC, Mukhtar H, Murray D. Evolution of imaging for abdominal perforation. *Ann R Coll Surg Engl.* 2010; 92: 182-8.
- Agresta F, De Simone P, Bedin N. The laparoscopic approach in abdominal emergencies: a single-center 10-year experience. *JLS.* 2004; 8: 25-30.
- Sauerland S, Agresta F, Bergamaschi R, Borzellino G, Budzynski A, Champault G. Laparoscopy for abdominal emergencies: evidence-based guidelines of the European Association for Endoscopic Surgery. *Surg Endosc.* 2006; 20: 14-29.
- Sinha R, Sharma N, Joshi M. Laparoscopic repair of small bowel perforation. *JLS.* 2005; 9: 399