

## Clay-Shoveler's Fracture Caused by Long-Term Bad Posture and Bad Habits: A Case Report

Wang Yuming<sup>1,2</sup> and Gong Huiming<sup>1,2</sup>

<sup>1</sup>School of Rehabilitation Medicine, Capital Medical University, Beijing 100068, China

<sup>2</sup>Department of Spinal and Neural Function Reconstruction, China Rehabilitation Research Center, Beijing 100068, China

### \*Corresponding author:

Gong Huiming,  
Department of Spinal and Neural Function  
Reconstruction, China Rehabilitation  
Research Center, Beijing 100068, China,  
E-mail: 15040407@qq.com

Received: 10 Feb 2022

Accepted: 28 Feb 2022

Published: 06 Mar 2022

J Short Name: ACMCR

### Copyright:

©2022 Gong Huiming. This is an open access article distributed under the terms of the Creative Commons Attribution License, which permits unrestricted use, distribution, and build upon your work non-commercially.

### Citation:

Gong Huiming, Clay-Shoveler's Fracture Caused by Long-Term Bad Posture and Bad Habits: A Case Report. Ann Clin Med Case Rep. 2022; V8(12): 1-3

### Keywords:

Clay-shoveler's fracture; Bad posture; Bad habits;  
Spinous process stress fractures

## 1. Abstract

**1.1. Objective:** To discuss the fracture of the spinous process of the lower cervical vertebra and upper thoracic vertebra due to long-term bad posture and bad habits, called Clay-Shoveler's fracture. Methods: To analyze the clinical diagnosis, treatment, rehabilitation and functional changes of one patient. Results: Combined with medical history, physical examination and imaging examination, the spinous process of the lower cervical vertebra and upper thoracic vertebra were caused by stress. After conservative rehabilitation treatment, the neck pain disappeared and the activity was normal.

**1.2. Conclusion:** Long-term bad posture and bad habits lead to a rare fracture of the spinous process of the lower cervical vertebra and upper thoracic vertebra.

## 2. Case

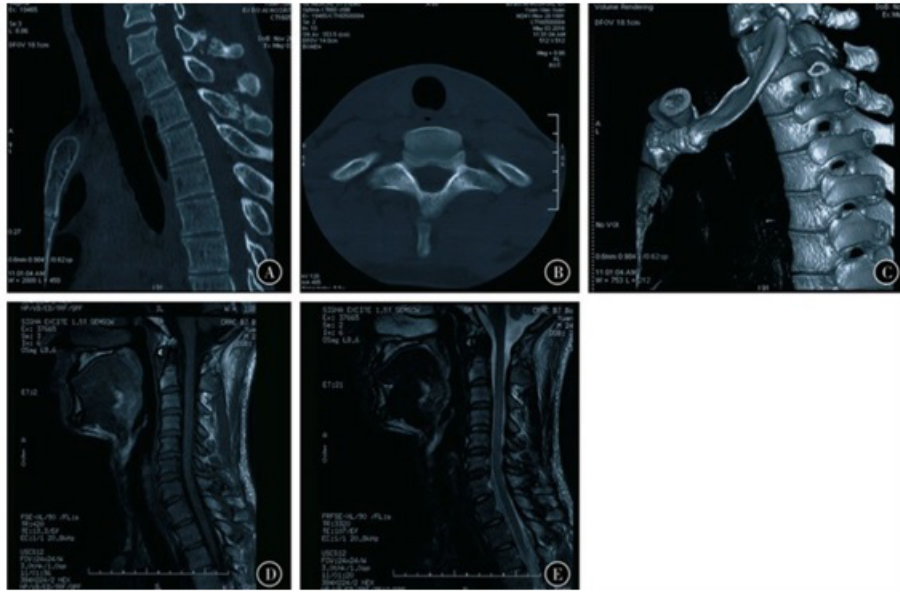
Male patient, 26 years old, whose main complaint was neck discomfort for more than 10 years, pain for 7 years, and exacerbation for 3 months. No previous history of trauma. The patient explained that he used to hold bad posture and movements of his head during childhood. He often feels that his neck is uncomfortable and the discomfort is located on the back of his neck, especially in the past 7 years. In the past 3 months, the visual analogue scale (VAS) score was 4 points. He often subconsciously take a head-lifting and side-tossed head motion to relieve neck discomfort and pain. The medical staff advised the patient to cease the above-mentioned undesirable actions to avoid aggravating the condition, but the patient did not follow the doctor's instructions. Physical examination:

No limb sensation, movement disorders, C7, T1, T2 spinous process tenderness, no spinal tapping pain. CT and MRI of the cervical thoracic segment showed longitudinal fracture lines of C7, T1, and T2 spinous processes, and no obvious callus formation was seen (Figure 1). Reconstruction of cervical spine CT display C7, T1, T2 spinous process fracture D. Sagittal MRI T1-weighted images of the cervical spine show C7, T1, T2 spinous process fractures E Sagittal MRI T2 weighted images of the cervical spine show C7, T1, T2 spinous process fractures Combined with the patient's medical history, physical examination, and imaging examination results, the diagnosis was C7, T1, T2 spinous process stress fracture. First, conservative treatment is given to patients to wear neck circumference to limit their neck movements to relieve pain. In the course of treatment, the focus of the first 4 weeks of exercise is to strengthen the upper body and core muscle groups, while gradually increasing work and study time. At this stage, the patient still has neck muscle spasms

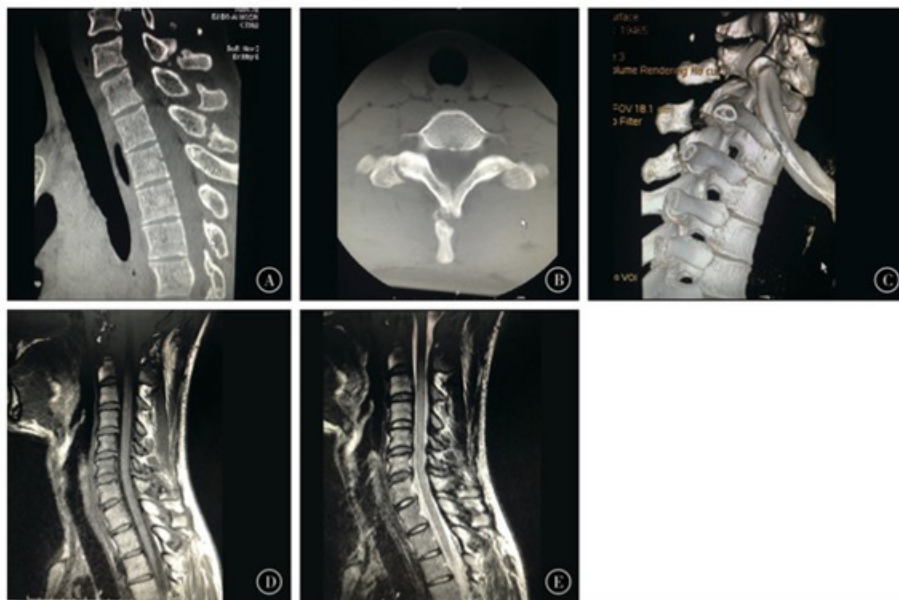and mild pain, and non-steroidal anti-inflammatory drugs can be applied symptomatically. Subsequently, massage, hot compress, and physical therapy were given for 4 weeks, and the functional exercises of the neck and back muscles were gradually strengthened, and work and learning were gradually increased. From 8 to 12 weeks after treatment, the patient still has discomfort in the lower cervical spine, upper thoracic spine, and paravertebral parts. The rotation and flexion and extension of the neck are not restricted, and he can gradually go back to normal work and study. After the treatment, the patient was instructed to keep strengthening the

core muscles. During the treatment, no neurological symptoms appeared. After 2 years of follow-up, there was no discomfort such

as pain, and the radiographic review showed the performance of old fractures (Figure 2).



**Figure 1:** CT and MRI imaging of cervical thoracic segment A. Cervical spine CT sagittal fracture C7, T1,T2 spinous process fracture B. cervical spine CT axial position spinous process fracture C. 3D.



**Figure 2:** The results of imaging after 2 years of follow-up A. Cervical spine CT sagittal showed C7, T1, T2 spinous process fractures did not heal. B Cervical spine CT axial position showed spinous process fractures did not heal. The medullary cavity was closed and the fracture ends were separated. C 3D reconstruction of the cervical spine CT shows C7, T1, T2 spinous process fractures unhealed D cervical sagittal MRI T1 weighted image shows C7, T1, T2 spinous process unhealed E cervical sagittal view MRI T2 weighted image shows C7, T1, T2 spinous process fractures unhealed.

### 3. Discussion

Clay-shoveler's fracture of spinous processes often occurs at C6 ~ T6 levels. Spinous process stress fractures are caused by direct trauma to the posterior neck when the trapezius and rhomboid muscles transmitted by the supraspinous ligament are in the flexed position. This is relatively rare clinically. Spinous process

stress fractures have been common among construction workers who have long been engaged in shoveling. With the development of industrial technology, it is rarely caused by shoveling labor or similar work at present, but rather caused mostly by sports training or injury [1-2]. Patients often have rotational movement of the upper spine when they are injured, that is, excessive flexion and ex-

tension of the spine [3]. The occurrence of spinous process stress fractures is not limited to any specific exercise. It can occur in horse riding, kayaking, paddle climbing, weight lifting, etc. [2-6]. Fractures caused by repetitive loads and overuse account for about 10% of all sports injuries [1]. Traffic accidents can also sometimes lead to stress fracture of the spinous process. Some patients developed osteoporosis after receiving corticosteroid therapy following kidney transplantation, and subsequently developed acanthosis fracture [7].

The occurrence of stress fracture of spinous process is related to local anatomic characteristics and functions. The cervical and thoracic spine process is long and tends to be horizontal. The posterior muscles of the trapezius, rhomboid, rhomboid, and serratus anterior are attached here. When the muscle contracts strongly, it exerts a lateral pull on the spinous process. Due to uneven forces on both sides, especially when one side of the muscle contracts and the other side of the muscle relaxes, the spinous process is fractured at the weak bone structure due to the repeated action of alternating forces. At the same time, when the muscle contracts, the stringy belt and the interspinous belt are in a state of tension [2]. Studies have shown that kayak rowing imposes significant alternating tension on the trapezius and rhomboid muscles attached to the T1 spinous process [3]. The mechanisms of stress fractures in the spinous process include direct force pulled by muscles, reflex muscle contraction, whip pull transmitted through the supraspinous ligament, indirect cervical hyperextension, and excessive flexion and avulsion, and muscle and ligament stress leading to fatigue fracture. The fracture line is usually located in the weakest part of the interspinous process, the broken end separated, the distal fragment usually displaced downward and laterally, and fracture failure is more common [8].

The stress fracture of spinous process is a stable fracture and can be treated conservatively. After analgesia and muscle relaxation, a Philadelphia collar and/or chest brace can be applied for 8 weeks. It is worth noting that the fixed time should be as short as possible, and the exercise should be started as early as possible after pain control [2]. Acupuncture, physical therapy, and other treatment can effectively relieve neck muscle spasm, promote blood and lymph circulation. Traction therapy is not recommended. This is because traction has no significant effect on the normal biomechanical structure of the cervical spine, and even has the disadvantage of straightening cervical physiological curvature.

#### 4. Summary

This case is really due to long-term poor posture leading to neck, shoulder, and back pain, with neck stiffness. The patient did not follow the doctor's advice, but alleviated the neck discomfort through action compensation and wrong action curing. Such a high frequency of repetitive wrong action increases the repetitive shear stress of trapezius and Rhomboid muscles, leading to C7, T1 and,

T2 spinous fractures, which are extremely rare. Multisegmental fractures of the spinous process are very rare. Once stress fracture of spinous process occurs, conservative treatment should be taken as soon as possible. Early diagnosis of CT and MRI is helpful to exclude stress fracture and nerve injury of spinous process.

#### References

1. Upadhyaya GK, Shukla A, Jain VK. Contiguous multiple cervicothoracic spinous process fractures in an adult: a case report [J]. *J Clin Orthop Trauma*. 2016; 7( 1): 45-49.
2. Posthuma de Boer J, van Wulfften Palthe AF,Stadhouder A. The Clay Shoveler 's fracture: a case report and review of the literature[J]. *J Emerg Med*. 2016; 51( 3 ): 292-297.
3. Olivier EC, Muller E, Janse van Rensburg DC. Clay-Shoveler fracture in a paddler: a case report[J]. *Clin J Sport Med*. 2016;26( 3): e69-70.
4. Kaloostian PE, Kim JE, Calabresi PA. Clay-shoveler's fracture during indoor rock climbing[J]. *Orthopedics*. 2013; 36( 3): e381-383.
5. Watson DJ, Dolbeer JA. C6 spinous process fracture in a young adult[J]. *J Orthop Sports Phys Ther*. 2017; 47( 9): 692.
6. Ok YC, Lee RS, Joe KY. A golf-related multiple spinous process fracture ( Clay-shoveler ' s fracture ) of cervico-thoracic spine: a case report[J]. *Korean J Neurotrauma*. 2008; 4( 2): 97.
7. Unay K, Karatoprak O, Sener N. A Clay-shoveler's fracture with renal transplantation and osteoporosis: a case report[J]. *J Med Case Rep*. 2008; 2:187.
8. Han SR, Sohn MJ. Twelve contiguous spinous process fracture of cervico-thoracic spine[J]. *Korean J Spine*. 2014; 11( 3): 212-213.