

# The Influence of CFTR Modulator Treatment on Chronic Rhinosinusitis in a Patient with Cystic Fibrosis – Case Report

Piotr Kwast<sup>1</sup>, Katarzyna Zybert<sup>2,3</sup>, Olga Olszewska-Sosińska<sup>1</sup>, Justyna Milczewska<sup>2,3</sup>, Maja Waszak<sup>1</sup>, Dorota Sands<sup>2,3</sup> and Lidia Zawadzka-Glos<sup>1</sup>

<sup>1</sup>Department of Pediatric Otolaryngology, Medical University of Warsaw, Poland

<sup>2</sup>Cystic Fibrosis Department, Institute of Mother and Children, Warsaw, Poland

<sup>3</sup>Cystic Fibrosis Center, Children's Hospital in DziekanówLeśny, Warsaw, Poland

## Corresponding author:

Piotr Kwast,

<sup>1</sup>Department of Pediatric Otolaryngology, Medical University of Warsaw, Poland

**Received Date:** 05 February 2024

**Accepted Date:** 24 February 2024

**Published Date:** 29 February 2024

## Citation:

Piotr Kwast. The Influence of CFTR Modulator Treatment on Chronic Rhinosinusitis in a Patient with Cystic Fibrosis – Case Report. *Annals of Clinical and Medical Case Reports* 2024.

## 1. Abstract

Most children with cystic fibrosis suffer from secondary chronic rhinosinusitis for which current treatment options are limited. Novel treatment for cystic fibrosis targeting the cause of the disease shows big promise in increasing pulmonary function, however its impact on sinus disease is not yet properly explored. We present a case of a teenager with chronic rhinosinusitis refractory to standard medical therapy and surgical treatment, who showed vast improvement in sinus disease after enrollment in CFTR modulator study. In this study we describe the patient's outcomes on sinus endoscopy and in patient-rated outcome measures together with improvement in lung function over the course of over two and a half years. Currently a growing body of evidence shows promising results of the novel treatment primarily on lung disease. Our findings shed a light on the impact of the currently rapidly developing modulator therapy for cystic fibrosis-related sinus disease.

## 2. Keywords:

Cystic Fibrosis; Chronic Sinusitis; Modulator Therapy

## 3. Introduction

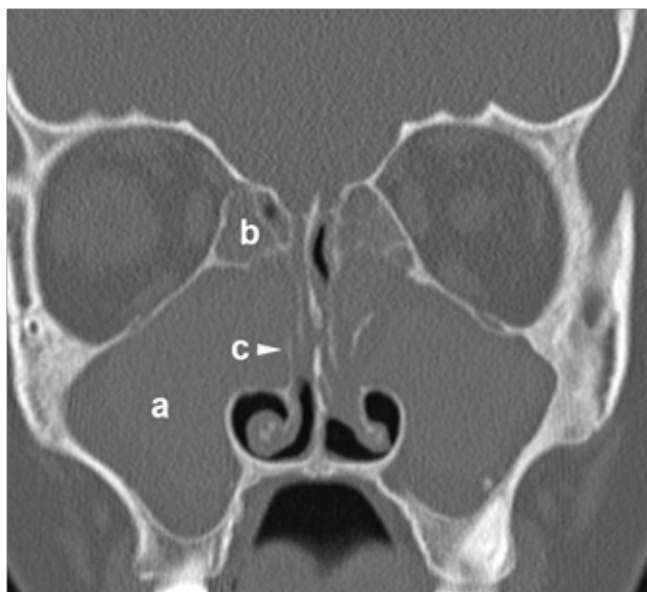
Majority of patients suffering from cystic fibrosis (CF) have chronic rhinosinusitis (CRS). Thickened secretion of the mucosa caused by variants of the CF transmembrane conductance regulator (CFTR) gene leads to mucus retention, bacterial infection and chronic inflammation within the sinuses. Current treatment options for CF-related CRS consist mainly of decreasing the inflammation with intranasal steroids, removing discharge with saline rinsing and surgical widening of sinus ostia during functional endoscopic sinus surgery (FESS) in order to improve mucus clearance. Exacerbations are treated with intravenous, oral or inhaled antibiotics. These methods help to relieve CRS symptoms in CF patients, but often fail to provide a long-lasting if not definite resolution of the disease [1]. Recent advancements in CF pharmacotherapy are dominated by the introduction of CFTR modulators. Since the introduction of ivacaftor in 2012 several substances have been studied and included in pharmacological treatment of CF. The most commonly reported outcomes of studies on CFTR modulators include weight gain, decrease in exacerbation rate and improvement in pulmonary function tests results. Very few studies analyze the impact of CFTR modulator therapy on CRS in CF patients [2]. The purpose of this work is to present the results of triple therapy with VX-659, tezacaftor and ivacaftor followed by elexacaftor, tezacaftor and ivacaftor in a teenage boy with CF-related CRS.

## 4. Case report

An 18-year-old boy with CF was diagnosed at the age of 9 months with sweat chloride test confirming characteristic symptoms such as malnutrition, fatty stools and recurrent pulmonary infections. Two CF-causing variants were identified in both alleles of the CFTR gene: F508del (class II) and 2183AA>G (class I). The patient developed all CF symptoms including pancreatic insufficiency. At the age of 10 months *Pseudomonas aeruginosa* (PA) was isolated from a throat swab for the first time. Beginning from the 6th year of life a chronic *Pseudomonas aeruginosa* and methicillin-susceptible *Staphylococcus aureus* (MSSA) lower respiratory tract infection was diagnosed. First inhaled gentamycin, then colistin and amikacin were introduced for treatment of the chronic PA infection. In 2014 (at the age of 11 years) chronic inhaled tobramycin was started and is administered until now. In 2016 a sinus CT scan was performed in order to assess the patient's sino-nasal disease, due to reported nasal blockage and recurrent nasal discharge. Scans from the study are shown in fig. 1. The patient filled out a Polish adaptation of SNOT-22 questionnaire, which assesses the impact on quality of life in patients reporting sino-nasal symptoms, with a result of 54 out of 110

# Annals of Clinical and Medical Case Reports

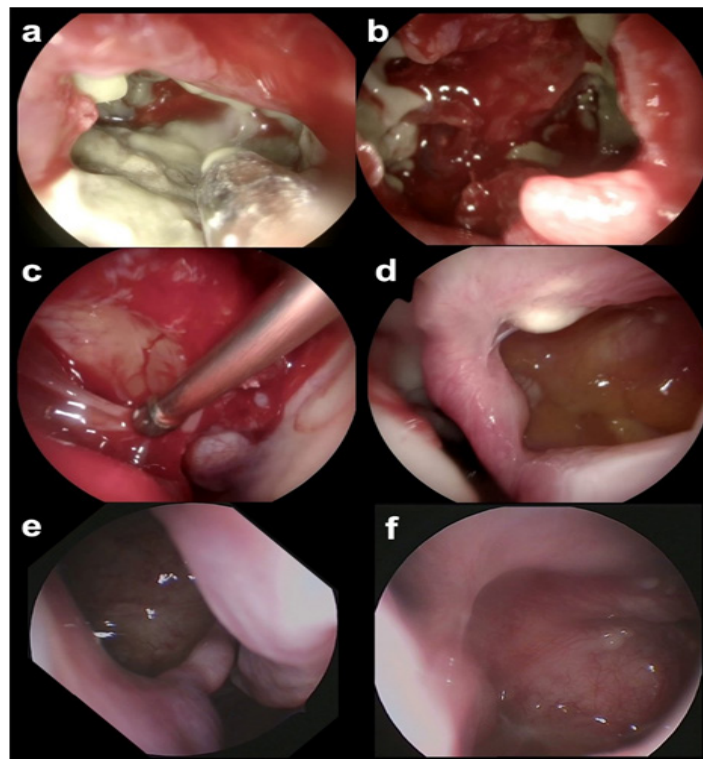
points.



**Fig 1:** CT of the paranasal sinuses before FESS and enrollment in the VX17-659-102 study. Complete of the maxillary (a) and ethmoid sinuses (b), as well as deformed medial walls of the maxillary sinuses (c) and polyps in the nasal cavities were found.

Since the patient was already receiving intranasal mometasone and performing nasal saline rinsing with unsatisfactory effect he was qualified for surgical treatment. Endoscopic sinus surgery was performed in 2017 with an oral ciprofloxacin course. Surgical findings included bilateral polyps obstructing the middle meatus and maxillary ostium as well as maxillary sinuses and anterior ethmoid cells with very thick purulent mucus (fig. 2a,b). Cultures taken from the sinuses revealed PA and MSSA etiology. Postoperative regimen included continued saline nasal lavage and intranasal administration of mometasone. During follow-up the patient reported nasal patency improvement and less nasal discharge. From the 1st of August 2018 the patient was enrolled in the VX17-659-102 study. So far this study has not been unblinded and we do not know if he received the study drug (VX-659 240 mg once daily + tezacaftor 100 mg once daily + ivacaftor 150 mg twice daily) or placebo. Over time since the first sinus surgery the symptoms of nasal obstruction recurred. In September of 2018 the patient scored 34 out of 110 points in the Polish adaptation of SNOT-22 questionnaire. On endoscopic examination polyps were found in the right middle meatus and the patient underwent a second FESS with a course of intravenous ceftazidime and colistin in January 2019. Findings (fig. 2c,d) included polyps in the right middle meatus and in the right maxillary sinus and polypoid overgrowth with mucosal abscesses in the left maxillary sinus. Little pus was found and cultures from the sinuses returned negative. Standard treatment with saline lavage and topical mometasone was continued. In January 2019 the patient completed the VX17-659-102 study and was immediately enrolled in the VX17-659-105 study, receiving VX-659 240 mg once daily + tezacaftor 100 mg once daily + ivacaftor 150 mg twice daily. In a follow-up examination 9 months after FESS and starting triple therapy the patient

reported a complete resolution of sinonasal symptoms including nasal discharge, nasal obstruction, headaches, smell impairment and postnasal drip. Complete resolution of CRS signs was found in endoscopy (fig. 2e,f). In the Polish adaptation of the SNOT-22 questionnaire the patient scored 5 out of 110 points.



**Fig 2:** Endoscopy findings: view of the right (a,c,e) and left (b,d,f) maxillary sinuses during first FESS in 2017 (a,b), second FESS in January 2019 (c,d) and nasal endoscopy in October 2019 (e,f).

Finally, in March 2020 he was transferred from the VX17-659-105 study to the VX18-445-113 study, receiving elexacaftor (VX-445) 200 mg once daily + tezacaftor 100 mg once daily + ivacaftor 150 mg twice daily. During the patient's participation in the VX17-659-102, VX17-659-105 and VX18-445-113 studies gradual improvement in forced expiratory volume in 1 second (FEV1) from 62% predicted in August 2018 up to 86% predicted in May 2021 was observed (Table 1). Also a significant improvement in nutritional status was noted, with his body mass index (BMI) standard deviation (SD) increasing from -1,17 (14th percentile) in August 2018 to -0,35 (38th percentile) in May 2021. During the VX17-659-102 and VX17-659-105 studies only 1 adverse event, a pulmonary exacerbation, treated with oral ciprofloxacin, has been reported. During VX18-445-113 study the patient was diagnosed of Gilbert's syndrome which is not related to the treatment he receives and he was also treated for Lyme disease.

**Table 1:** Patient's FEV1 and BMI SD before and during participation in the VX17-659-102, VX17-659-105 and VX18-445-113 studies.

Date	FEV1	BMI SD
28-Aug-18	62%	-1.17
17-Dec-18	67%	-1.2
25-Jan-19	91%	-1.2
13-May-20	93%	0.87
24-May-21	86%	-0.35

## 5. Discussion

Sino-nasal disease is found in almost all patients with cystic fibrosis (3, 4, 5), with fully symptomatic CRS diagnosed in about 60% [6]. CF-related CRS presents differently from primary CRS, with mild symptoms and severe radiological manifestation. The importance of CRS treatment in CF patients has been brought up with increasing frequency over the previous years. An impact of sinusitis on both quality of life and severity of lower airway disease is postulated [6, 7]. Current treatment options in patients with CF-related CRS are limited. The mainstay of conservative management includes nasal irrigation and topical steroids, although available data to back up the effectiveness of these methods of treatment is very limited [8]. Sino-nasal vibrating inhalation with both 6% and 0.9% NaCl showed minimal improvement of symptoms in CF-related CRS [9]. Topical dornase alpha was shown to have a positive effect in two studies [10, 11], however due to high cost, this method of treatment is rarely used. Both topical Colistin and Tobramycin have been found to reduce the bacterial load in the sinuses [7, 12]. Only two studies analyzed the effect of topical steroids on CRS in CF patients with positive effect, of which one was prospective [13, 14, 15]. Data regarding treatment in children is even more limited. While both saline irrigation and topical steroids are widely believed to be safe in children, their positive effect on disease course is uncertain [4, 5]. The presented patient was treated conservatively with intranasal steroids and nasal lavage with minor improvement before surgical treatment was introduced.

Surgical management of CF-associated CRS is widely accepted as endoscopic sinus surgery has been found to be effective in decreasing symptoms of CRS [16]. Surgery can be seen as an aid in conservative management of more severe cases [16]. FESS in children with cystic fibrosis is considered to be safe [17, 18], however there is a wide variation in frequency of FESS performed in children with CF in different hospitals [18]. FESS facilitates a better penetration of intranasal steroids and better debridement with saline lavage but does not target the cause of CF-related CRS. Some studies have shown improvement in quality of life after FESS [19], while the expected positive impact on lung function has not been proven [20]. Novel treatment options based on CFTR modulators such as ivacaftor, lumacaftor, tezacaftor and most recently elexacaftor appeared over the last decade. Ivacaftor, a CFTR potentiator, introduced in 2012 is the first introduced CFTR modulator. It increases ion flow through dysfunctional CFTR chloride channel [21]. In monotherapy it is applicable in less than 10% of CF patients, as only some genotypes are susceptible to this treatment alone [21]. In 2015 a new treatment option emerged for a wider population of CF patients, as Ivacaftor in combination

with lumacaftor, a CFTR corrector, was approved for treatment in patients homozygous for the F508del -variant [21]. Lumacaftor, as well as the newer tezacaftor and elexacaftor increase the presence of the CFTR channel on the cell membrane. Patients receiving CFTR modulators in various combinations show improvements in lung function and overall quality of life with very few studies reporting results regarding sinus symptoms [2, 22]. The newest combination of ivacaftor, tezacaftor and elexacaftor (so-called “triple therapy”) is proven to be effective in patients with one copy of the F508del variant, which means it can have effect in about 90% of the population suffering from CF [23]. Triple therapy has been found to improve both FEV1, pulmonary symptoms and sweat chloride tests in patients with one or two copies of the F508del variant [23, 24]. Sino-nasal outcomes of CFTR modulator treatment are not yet vastly explored, with only a few studies focusing on them up to date. Chang et al. first reported a case of dramatic improvement of CRS symptoms as well as airway surface liquid pH and viscosity in an adult with a G551D CFTR variant after 10 months of receiving ivacaftor in monotherapy [25]. The impact on sinus disease of triple therapy with ivacaftor, tezacaftor and elexacaftor has been shown in a significant decrease of SNOT-22 results in 43 adult patients after 3 months of treatment by DiMango et al. [26] and in a varied period after initiation of therapy by Douglas et al. [27].

## 6. Conclusion

The improvement in our patient was visibly larger than in other children with CF undergoing FESS. With such observations there is hope for modulator therapy to have a vast positive impact on CF-related CRS treatment and further investigations will show whether triple therapy or any novel CFTR modulator treatment has the potential to even prevent sinus surgery in CF-related CRS. With a growing number of patients receiving novel modulator treatment, also among children, subsequent large-scale studies are needed to show a definitive positive impact of modulator therapy on sino-nasal disease in cystic fibrosis.

## References

1. Tipirneni KE, Woodworth BA. Medical and Surgical Advancements in the Management of Cystic Fibrosis Chronic Rhinosinusitis. *Curr Otorhinolaryngol Rep.* 2017;5(1):24-34.
2. Spielman DB, Beswick DM, Kimple AJ, Brent AS, Kasper A, Bradford AW, Rodney JS, et al. The management of cystic fibrosis chronic rhinosinusitis: An evidenced-based review with recommendations. *Int Forum Allergy Rhinol.* 2022;12(9):1148-1183.
3. Sands D et al. Mukowiscydoza, choroba wieloukładowa. Termedia 2018.
4. Johnson BJ, Choby GW, O'Brien EK. Chronic rhinosinusitis in patients with cystic fibrosis-Current management and new treatments. *Laryngoscope Investig Otolaryngol.* 2020;5(3):368-374.
5. Safi C, Zheng Z, Dimango E, Keating C, Gudis DA. Chronic Rhinosinusitis in Cystic Fibrosis: Diagnosis and Medical Management. *Med Sci (Basel).* 2019;7(2):32.
6. Berkhout MC, van Rooden CJ, Rijntjes E, Fokkens WJ, elBouazzaoui

# Annals of Clinical and Medical Case Reports

- LH, Heijerman HG. Sinonasal manifestations of cystic fibrosis: a correlation between genotype and phenotype?. *J Cyst Fibros*. 2014;13(4):442-448.
7. Aanaes K. Bacterial sinusitis can be a focus for initial lung colonisation and chronic lung infection in patients with cystic fibrosis. *J Cyst Fibros*. 2013 Sep;12 Suppl 2:S1-20.
  8. Krajewska J, Zub K, Słowikowski A, Zatoński T. Chronic rhinosinusitis in cystic fibrosis: a review of therapeutic options. *Eur Arch Otorhinolaryngol*. 2022;279(1):1-24.
  9. Mainz JG, Schumacher U, Schädlich K, et al. Sino nasal inhalation of isotonic versus hypertonic saline (6.0%) in CF patients with chronic rhinosinusitis - Results of a multicenter, prospective, randomized, double-blind, controlled trial. *J Cyst Fibros*. 2016 Nov;15(6):e57-e66.
  10. Mainz JG, Schien C, Schiller I, et al. Sinonasal inhalation of dornase alfa administered by vibrating aerosol to cystic fibrosis patients: a double-blind placebo-controlled cross-over trial. *J Cyst Fibros*. 2014 Jul;13(4):461-70.
  11. Cimmino M, Nardone M, Cavaliere M, et al. Dornase alfa as postoperative therapy in cystic fibrosis sinonasal disease. *Arch Otolaryngol Head Neck Surg*. 2005 Dec;131(12):1097-101.
  12. Mainz JG, Schädlich K, Schien C, et al. Sinonasal inhalation of tobramycin vibrating aerosol in cystic fibrosis patients with upper airway *Pseudomonas aeruginosa* colonization: results of a randomized, double-blind, placebo-controlled pilot study. *Drug Des Devel Ther*. 2014;8:209-217.
  13. Hadfield PJ, Rowe-Jones JM, Mackay IS. A prospective treatment trial of nasal polyps in adults with cystic fibrosis. *Rhinology*. 2000 Jun;38(2):63-5.
  14. Donaldson JD, Gillespie CT. Observations on the efficacy of intranasal beclomethasone dipropionate in cystic fibrosis patients. *J Otolaryngol*. 1988 Feb;17(1):43-5.
  15. Beer H, Southern KW, Swift AC. Topical nasal steroids for treating nasal polyposis in people with cystic fibrosis. *Cochrane Database Syst Rev*. 2015;2015(6):CD008253.
  16. Fokkens WJ, Lund VJ, Hopkins C, et al. European Position Paper on Rhinosinusitis and Nasal Polyps 2020. *Rhinology*. 2020 Feb 20;58(Suppl S29):1-464.
  17. Tumin D, Hayes D Jr, Kirkby SE, et al. Safety of endoscopic sinus surgery in children with cystic fibrosis. *Int J Pediatr Otorhinolaryngol*. 2017 Jul;98:25-28.
  18. Virgin FW, Huang L, Roberson DW, Sawicki GS. Inter-hospital variation in the frequency of sinus surgery in children with cystic fibrosis. *Pediatr Pulmonol*. 2015 Mar;50(3):231-235.
  19. Fetta M, Tsilis NS, Segas JV, et al. Functional endoscopic sinus surgery improves the quality of life in children suffering from chronic rhinosinusitis with nasal polyps. *Int J Pediatr Otorhinolaryngol*. 2017 Sep;100:145-148.
  20. Yin M, Gao X, Di L, et al. Effect of Endoscope Sinus Surgery on Pulmonary Function in Cystic Fibrosis Patients: A Meta-Analysis. *Laryngoscope*. 2020 Sep 19.
  21. Burgener EB, Moss RB. Cystic fibrosis transmembrane conductance regulator modulators: precision medicine in cystic fibrosis. *Curr Opin Pediatr*. 2018;30(3):372-377.
  22. Mall MA, Brugha R, Gartner S, et al. Efficacy and Safety of Elexacaftor/Tezacaftor/Ivacaftor in Children 6 Through 11 Years of Age with Cystic Fibrosis Heterozygous for F508del and a Minimal Function Mutation: A Phase 3b, Randomized, Placebo-controlled Study. *Am J Respir Crit Care Med*. 2022;206(11):1361-1369.
  23. Davies JC, Moskowitz SM, Brown C, et al; VX16-659-101 Study Group. VX-659-Tezacaftor-Ivacaftor in Patients with Cystic Fibrosis and One or Two Phe508del Alleles. *N Engl J Med*. 2018 Oct 25;379(17):1599-1611.
  24. Burgel PR, Durieu I, Chiron R, et al. French Cystic Fibrosis Reference Network study group. Rapid Improvement After Starting Elexacaftor-tezacaftor-ivacaftor in Patients with Cystic Fibrosis and Advanced Pulmonary Disease. *Am J Respir Crit Care Med*. 2021 Feb 18.
  25. Chang EH, Tang XX, Shah VS, et al. Medical reversal of chronic sinusitis in a cystic fibrosis patient with ivacaftor. *Int Forum Allergy Rhinol*. 2015 Feb;5(2):178-81.
  26. DiMango E, Spielman DB, Overdeest J, et al. Effect of highly effective modulator therapy on quality of life in adults with cystic fibrosis. *Int Forum Allergy Rhinol*. 2021 Jan;11(1):75-78.
  27. Douglas JE, Civantos AM, Locke TB, et al. Impact of novel CFTR modulator on sinonasal quality of life in adult patients with cystic fibrosis. *Int Forum Allergy Rhinol*. 2021;11(2):201-203.